

産婦人科に関心のある先生へ

産婦人科の魅力は配偶子（精子や卵子）から老いに至るまで女性の全てのライフステージに関わっていけることです。

産科、婦人科良性疾患、婦人科悪性腫瘍、不妊、内分泌異常や更年期などの女性医学などの subspeciality も広く、必要とされる医学的知識や技術も超音波、遺伝学、分娩各種手技、内視鏡手術、腹式手術、膣式手術、腫瘍学、内分泌動態と多岐に渡っています。

また、患者への高い説明能力、交渉能力を必要とされる機会も多いのが産婦人科の特徴です。

外科的スキルと内科的発想とコミュニケーションスキルの絶妙な融合で患者に最良の治療を提供するのはまさに art といえるでしょう。

ハードルは高いですが越えた先に素晴らしい景色が見えてくるはずです。是非一緒に学びましょう。

婦人科腹腔鏡手術について

腹腔鏡下手術の利点は開腹手術と比べて①低侵襲で術後の痛みが少なく回復が早い、②スコープにより術野を拡大して観察できるのでより繊細な手術が可能、③出血が少ない、④傷が小さく美容上優れている、⑤術後腹腔内癒着が少ない、⑥腹腔内の深く狭い空間の操作が可能などのメリットが挙げられますが手術手技の習得に熟練を要します。

この原因には可動性の制限された長い鉗子操作が難しい、触感に乏しい、立体視認識に時間を要することなどがあります。

しかし、これらを克服することで格段に high quality な手術を表現することが可能になります。

婦人科腹腔鏡のスキルの向上には A 骨盤解剖の認識、B 縫合結紮技術向上、C 癒着や止血を見極める目の養成が必要だと考えます。これらの理由について概説すると、

A; expert の手術は流れるようなリズムがあります。素早く大きく開放する腔と細かく慎重に開く層なのかの判断にはランドマークとしての解剖を層で認識することが要求されます。

B;最近はデバイスの進化による無結紮、無縫合の手術も増えてきていますがトラブルシューティングや再建手術の際にもものを言うやはり縫合結紮です。日々の怠らぬ練習が必要です。

C;止めなくてはいけない出血とそうでない出血があります。同様に癒着にも強固であるか filmy であるか粘調か dry か広範か局所かの違いがあります。この違いを見抜く目を養成し正常にあったデバイスや鉗子の選択ができることが望まれます。

今回、この縫合結紮について筆者がこれまでに作成した動画および資料を紹介しますので参考に活用して頂けたら幸いです。

いくら早くても乱暴な縫合はいけません。日々の素振りで綺麗な軌道を描き美しさにこだわってください。美は真なり。

腹腔鏡技術認定医の取得を目指す先生へ

当院は日本産科婦人科内視鏡学会認定研修施設です。

専門医を取得し、日本産科婦人科内視鏡学会に所属している先生が資格取得し執刀できるような2年間のプログラムを提供します。

腹腔鏡下手術の技術向上には以下の3つをバランス良く且つ豊富にこなしていくことが必要です。

- ① ドライボックスを用いた練習
- ② 上級医の手術の見学
- ③ 実際の執刀と助手

これらについて各々説明していきます。

- ① ドライボックスを用いた練習：入職したら速やかに個人所有のトレーニングボックス、鉗子、ビデオカメラ、モニターを準備してもらいます。朝夕最低20分のトレーニングを日課とします。内容は上達に応じて上級医から指導します。

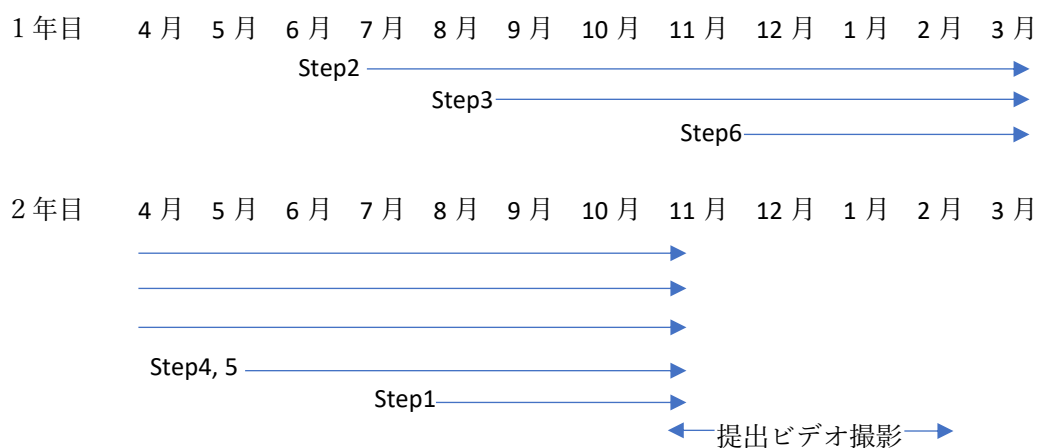
- ② expert の手術を学ぶ機会を実際の現場や動画で提供します。定型化された術式を身につけ、鉗子や device の選択や手の動き、音などを見極める感性を涵養しましょう。
- ③ 研修開始後、間も無く助手を務め次第に執刀を開始します。手術の緊張感、リズム、触感、ドライボックスとの違いを体感し術者としての自立を促します。

当院では以下の定型化した腹腔鏡下腔式子宮全摘術に準拠してトレーニングを行います。

- Step 1 子宮動脈と尿管の同定
- Step 2 上部靭帯の切離
- Step 3 傍子宮組織の処理
- Step 4 腔管切開
- Step 5 子宮の腔式回収
- Step 6 腔断端と後腹膜の縫合

時期と経験症例と個人の skill に応じて多少の前後はありますが徐々に執刀医としての task を増やしていきます。

(例) 4 月入職の場合



技術認定医取得はあくまでも通過点です。世界に通用する expert を目指すような高い意識で修練する先生の応募をお待ちしています。

動画配信 YouTube

<https://www.youtube.com/watch?v=g6dv-EbXkkg&t=27s>

<https://www.youtube.com/watch?v=tWeR9goEow4>

<https://www.youtube.com/watch?v=rKpPhyCuNPg>

Laparoscopic Suturing

Akira Shirane

Introduction

Energy devices have advanced dramatically over the past decade, decreasing a surgeon's reliance on laparoscopic suturing, however for complex surgeries, suturing skill remains vitally important. Vascular, bowel and urinary tract injuries necessitate skilled repair using suture. Severe adhesions, malignancy and deeply invasive endometriosis increase the risk of injury and bleeding, necessitating advanced suturing techniques. Advanced skills enable the surgeon to overcome these situations safely.

Laparoscopic surgery requires a perfect command of long shafted instruments, an economy of motion and different haptic sensation. The visual perspective is altered from laparotomic anatomy. Delivery of needles and suture into the abdominal cavity may also present a challenge. Finally, the landscape of anatomy and disease may demand a variety of suturing techniques to effectively control bleeding, restore anatomy or repair injuries.

General principles

This chapter presents a stylistic approach to advanced laparoscopic suturing.

- Strategy for port placement
- Instrumentation
- Needle entry into abdomen
- Basic suturing tips
- Suture ligation
- Needle handling and positioning
- Seven techniques for laparoscopic surgeon's knot

Cannula placement

The 'Modified Diamond Configuration' for cannula placement in benign surgical cases is ideal. One port is placed few centimeter above between pubic bone at the midline, one at the umbilicus and two, bilateral just medial to the anterior superior iliac spine. For complex or malignant cases, a modified diamond configuration plus one cannula for manipulation and exposure are best.

Figure 1. Modified Diamond Configuration

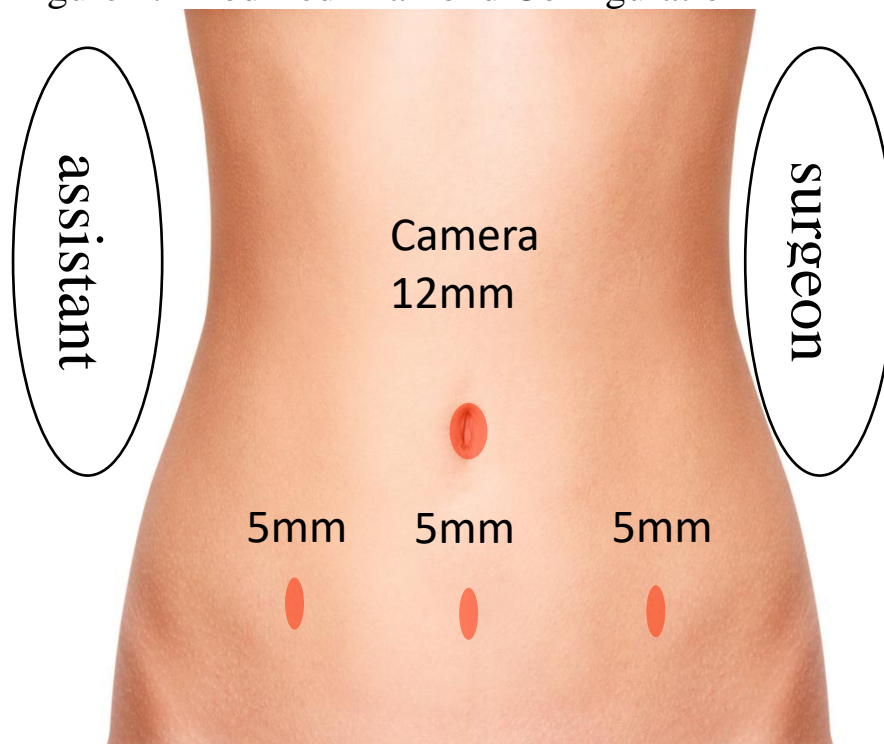


Figure 2. Modified diamond configuration plus one cannula for additional retraction and manipulation is ideal for complex cases.

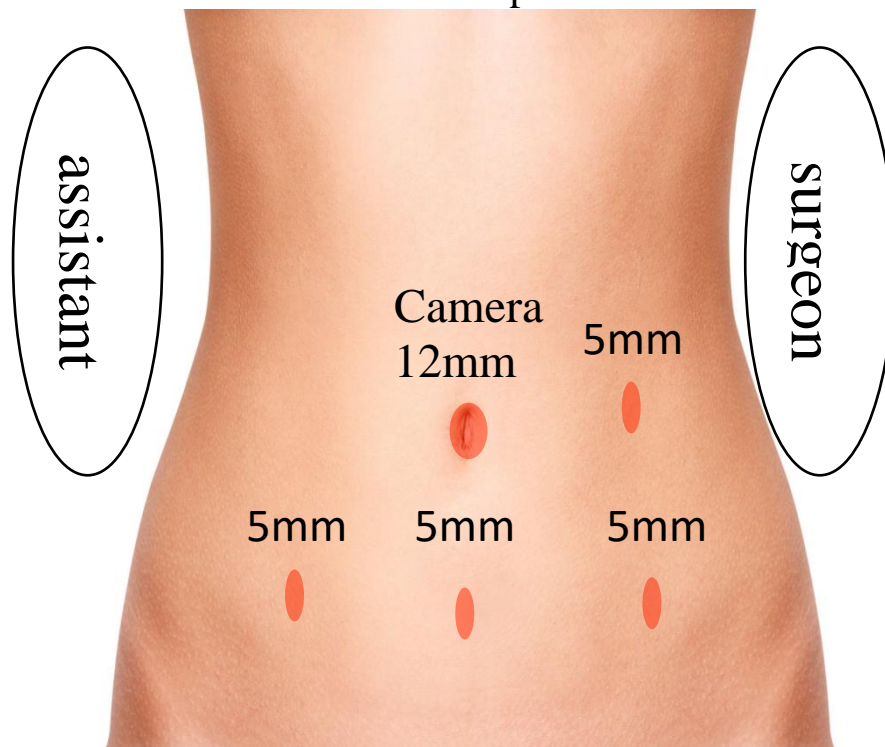
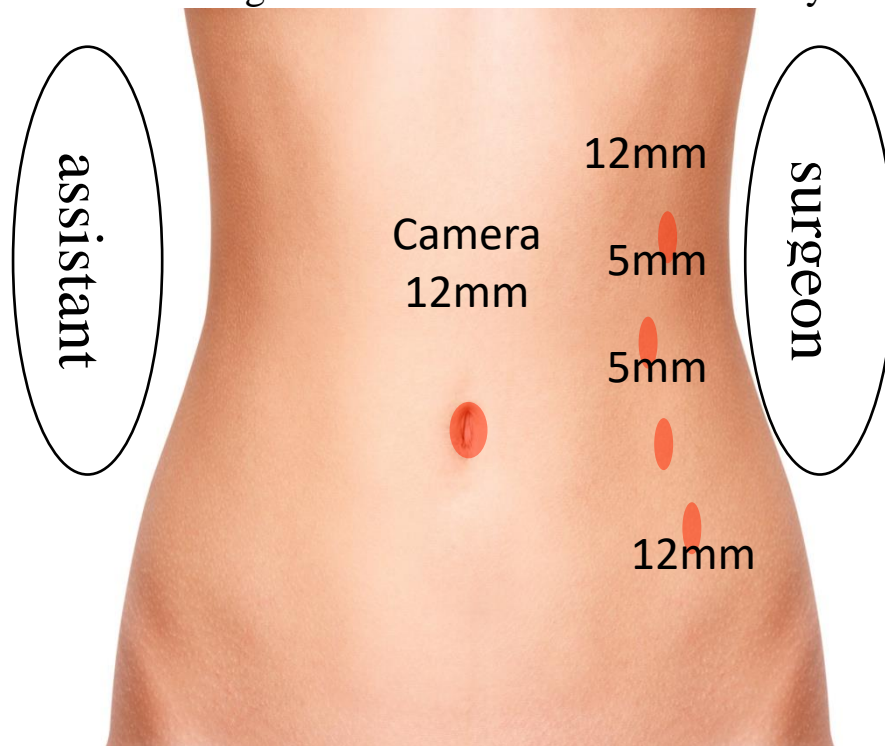


Figure 3. Cannula placement for para-aortic lymphadenectomy via the left retro-peritoneal approach: Following lymph node dissection two cannulas on right and center lower abdomen may be added.



Instruments and suture

The surgeon uses a straight needle driver or grasper with the dominant hand and a dissector with the non-dominant hand. Some surgeons may prefer to use 2 needle drivers, however this may compromise tissue handling.

For training purposes, a curved needle with absorbable suture is preferred. Surgical cases will demand different suture based on structure and anatomy.

Needle Entry

There are four ways to introduce a curved needle into the abdomen.

Through a port site

Surgeon may insert a less than 48mm curved needle through a 5-mm incision directly into cavity.

The suture is grasped 2 cm above the swedge of the needle and introduced directly through a 5-mm incision. While introducing the needle, an assistant monitors laparoscopically to avoid injury.

Figure . The needle is introduced directly through the abdominal incision (port site).

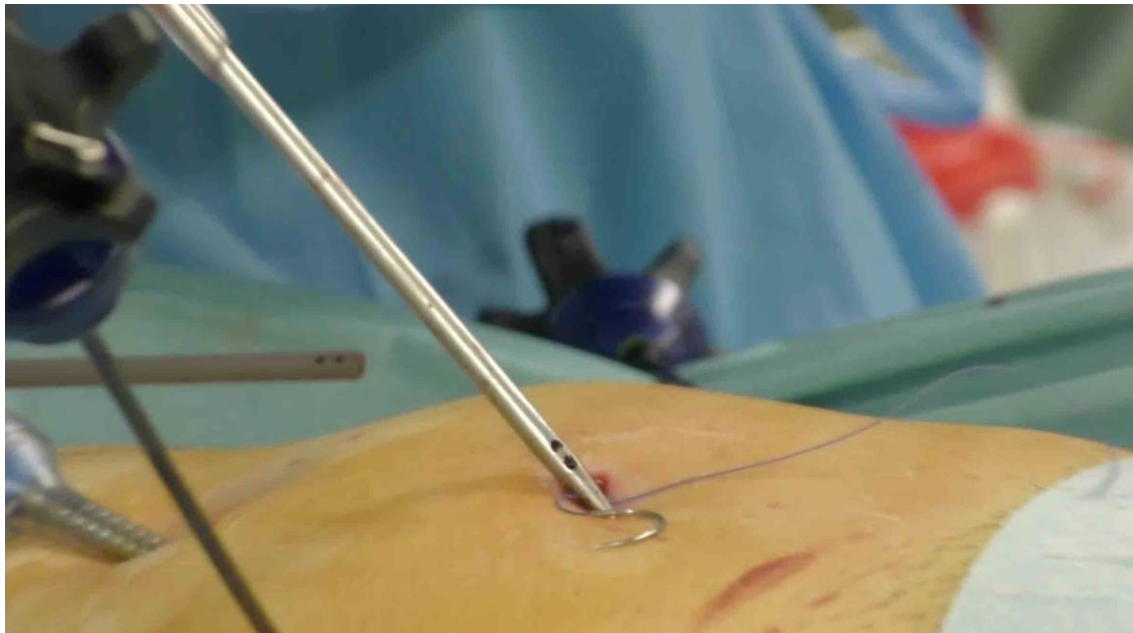
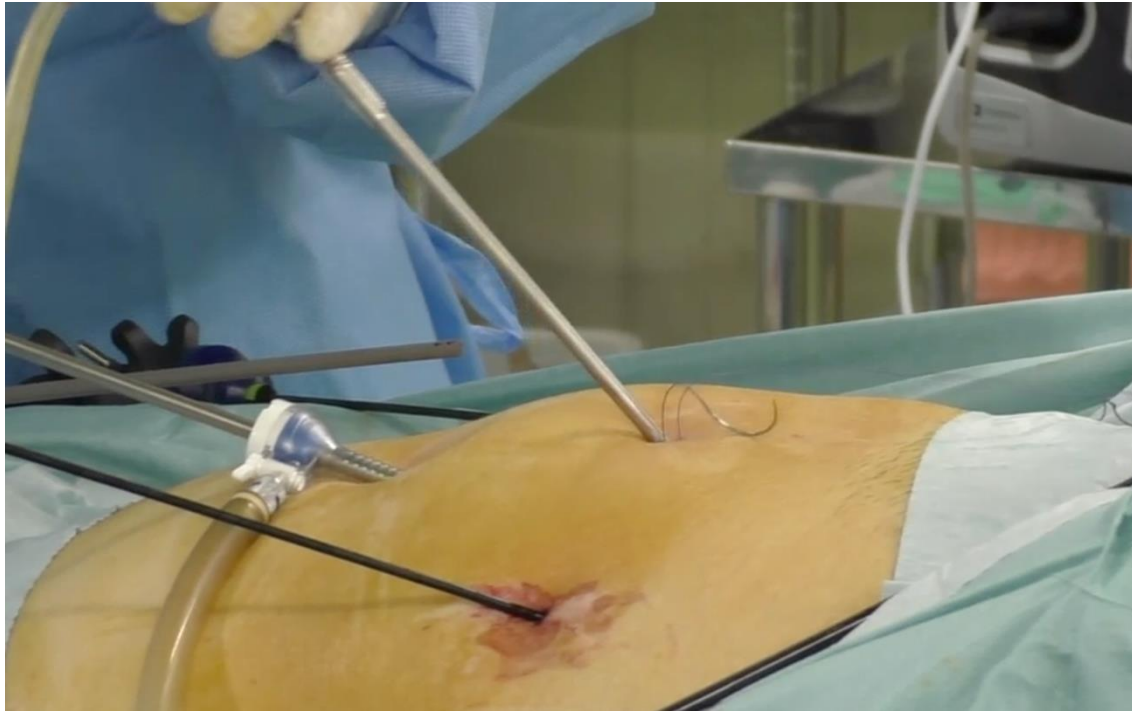


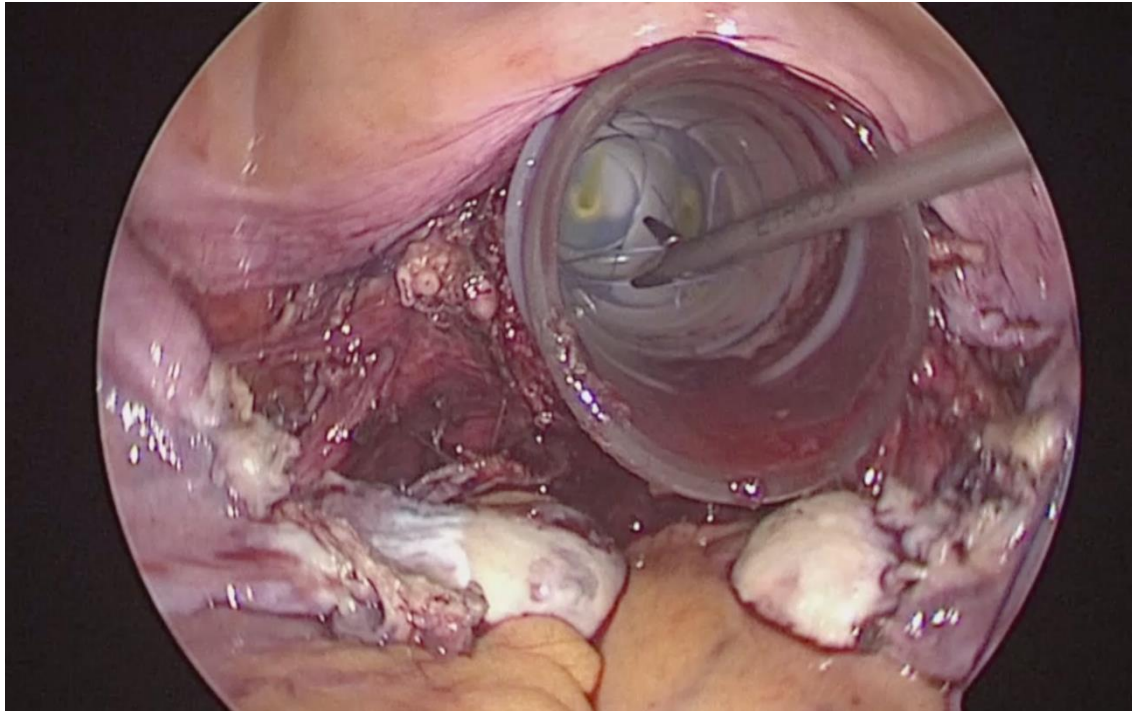
Figure . Grasp the suture 2 cm above the swedge and insert through the incision under direct visualization with the laparoscope.



Transvaginal approach

Following colpotomy, the needle may be advanced into the abdomen through the vagina. Vaginal preparation is performed at the onset of all cases to prevent infection. Some surgeons may prefer to use a protective tube in the vagina, however this is not always necessary. Needles may then be removed, following cuff closure, with one of the other methods of entry.

Figure . Introduce the needle into the abdomen through the vagina before closing the vaginal cuff.



Through the cannula

Curved needles smaller than 36 mm may be passed through the 12-mm cannula sleeve.

The suture is grasped 2 cm above the swedge of the needle and introduced directly through the cannula.

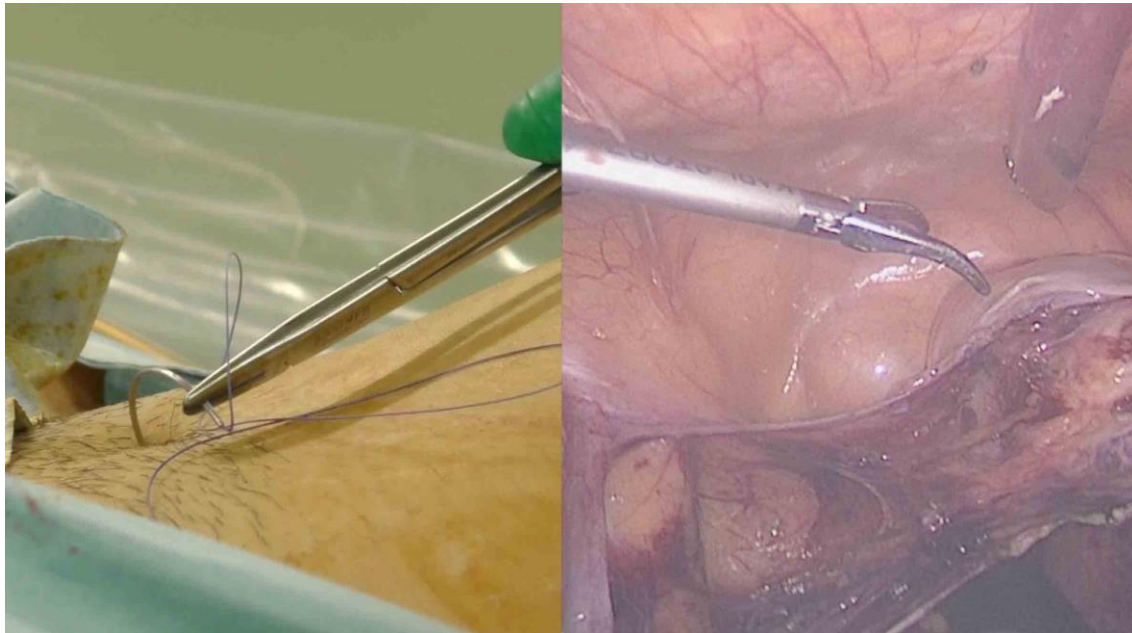
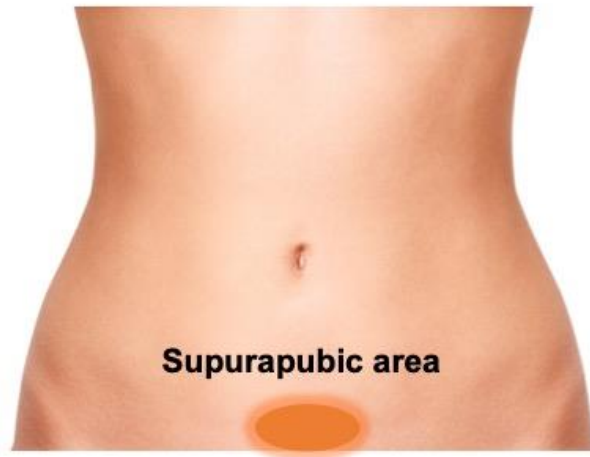
Figure . Grasp the suture 2 cm above the swedge of the needle and insert through a 12 mm cannula.

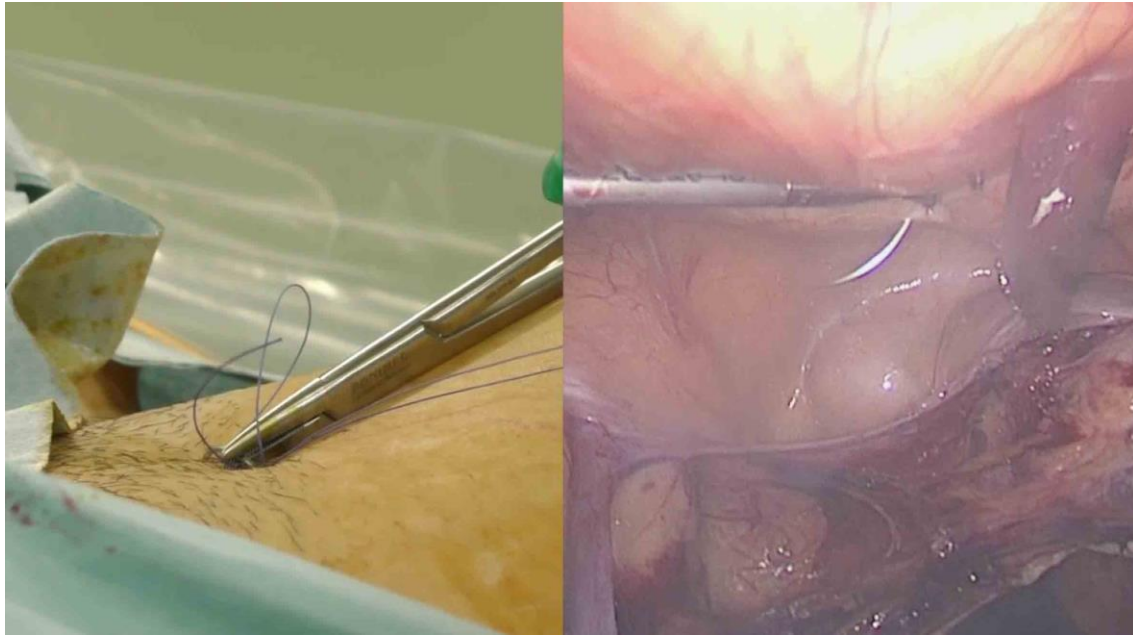


Through the abdominal wall

When a larger needle is required, it may be inserted percutaneously through the abdominal wall. The suprapubic area generally has less fat and is suitable for insertion of the needle.

Figure . The suprapubic area is generally thinner and suitable for needle entry.





Basic Suturing Tips

“Move the Ground”

“Move the ground” means to change the location of targeted organs or tissues in order to suture them more efficiently. In laparoscopic surgery, forceps-motion is considerably limited compared with open surgery. In addition, the work space may be deep and narrow. Bringing the target organs or tissues into a more optimal position by having an assistant manipulate and orient the tissue optimizes the best suturing techniques.

“**Move the Ground**” is one of the most important secrets to suturing quickly and precisely.

“Grab a Needle and a Thread”

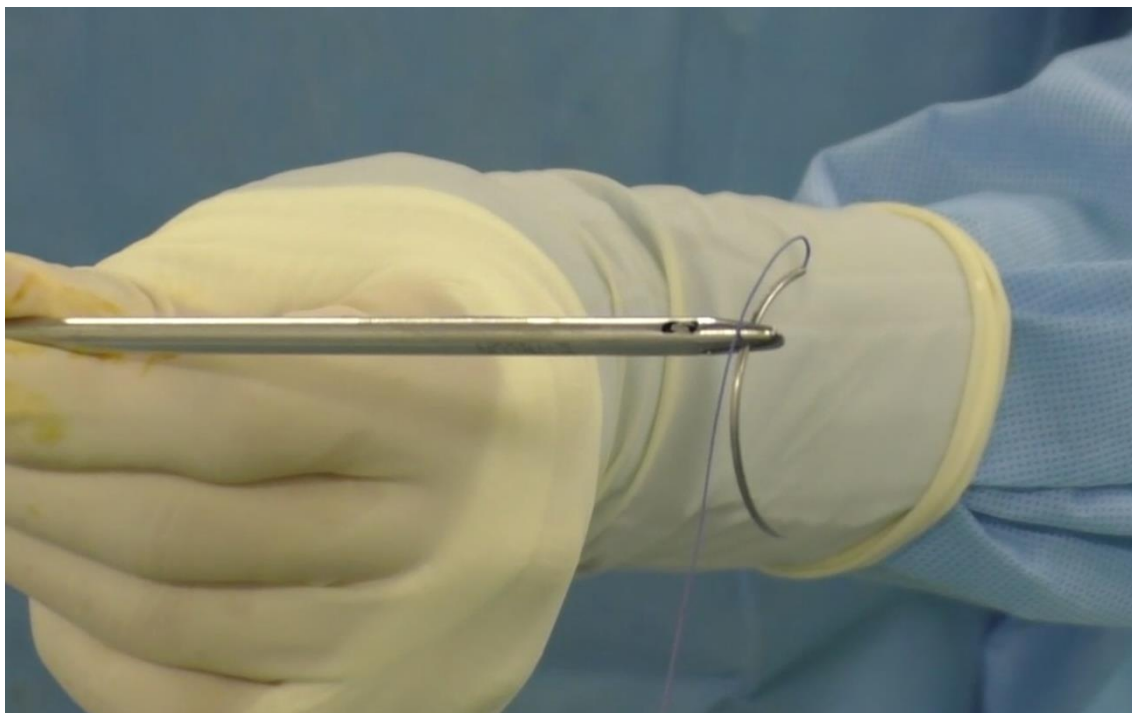
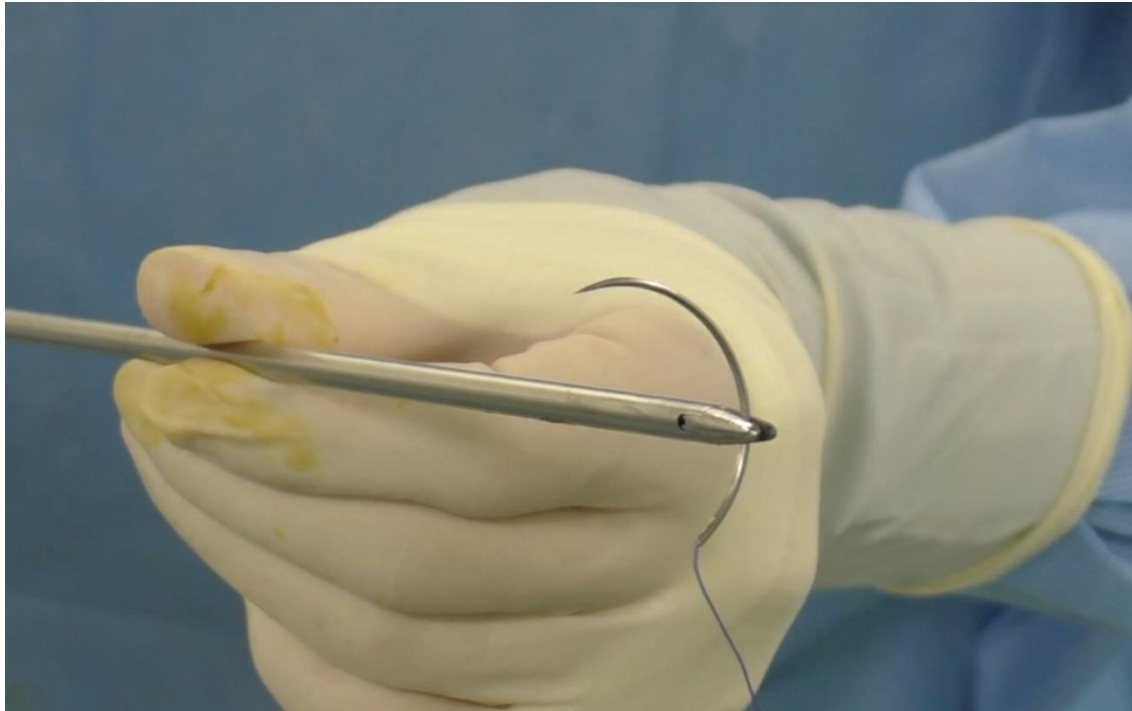
In laparoscopic surgery, there may be a loss of depth or perspective. In open cases, the needle is held perpendicular to the needle driver, however in laparoscopic surgery, it may be difficult to achieve this due to the altered perspective.

One can check whether the angle is correct by rotating the needle driver with a needle. Alternatively one can hold it vertically by twisting your needle driver just before closing blade of driver.

Figure . When grasping the needle, turn the wrist toward the tip of the needle to grasp it vertically.

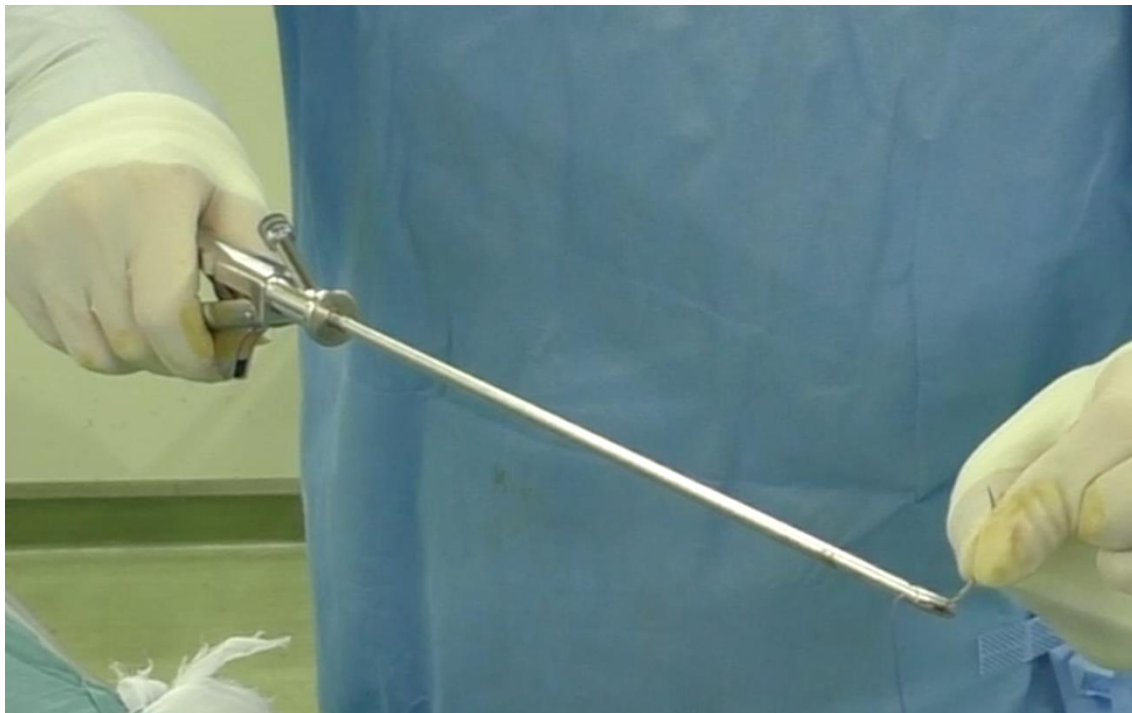

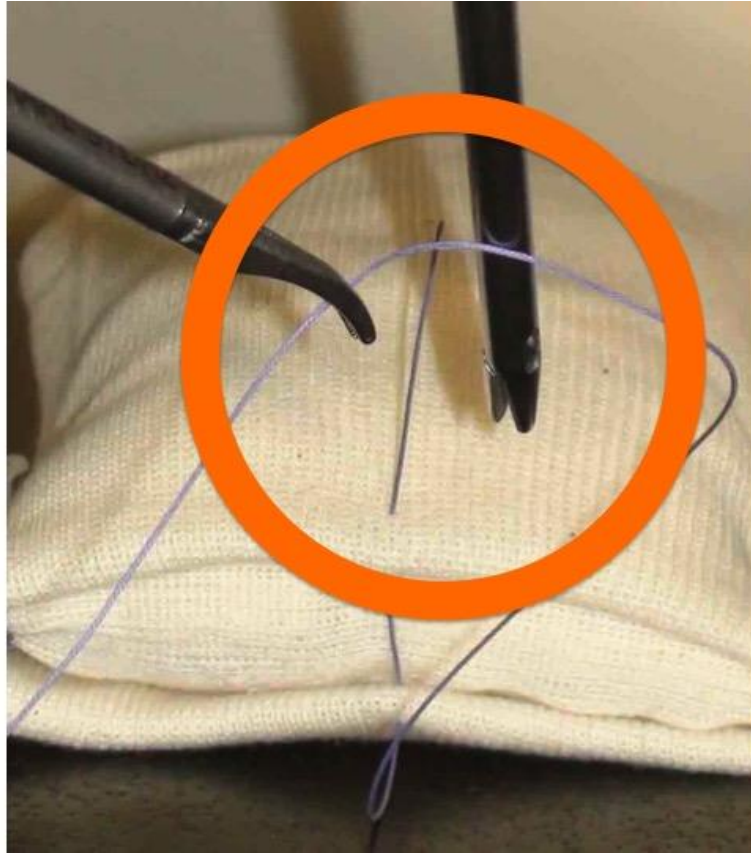
Figure . Hold the needle vertically with the grasper.



Suture management

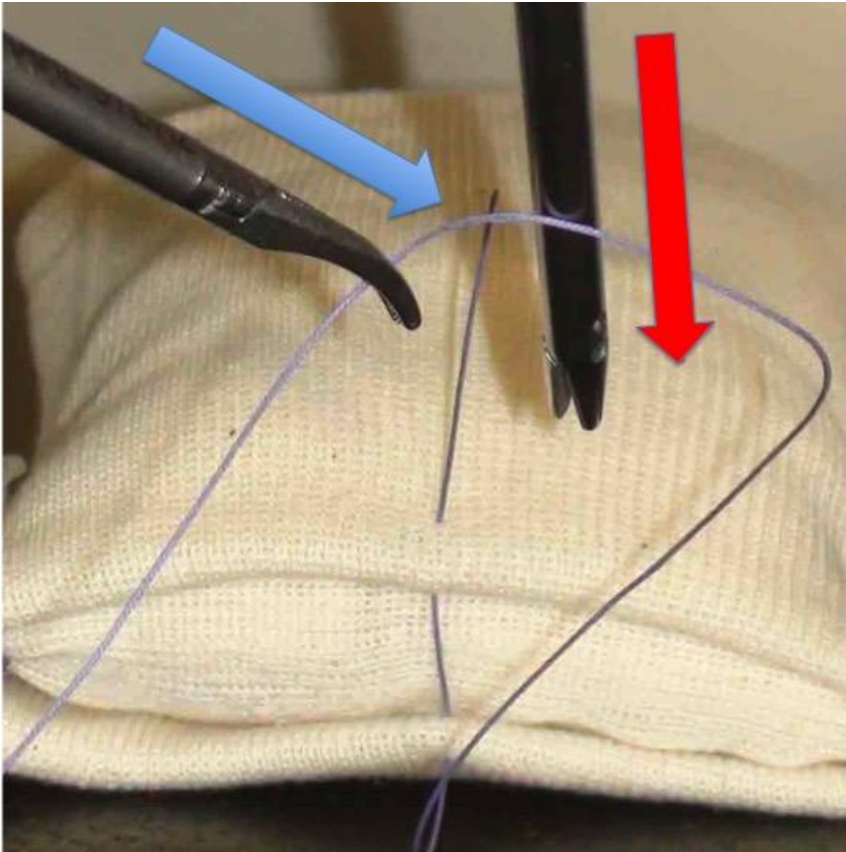
- 1) Always work within a specified small area. “Pull a thread, grab a needle” means to bring the suture and needle into a confined work-space, rather than using a large area while suturing..

Figure . The tips of the forceps should work within a small circle as much as possible.



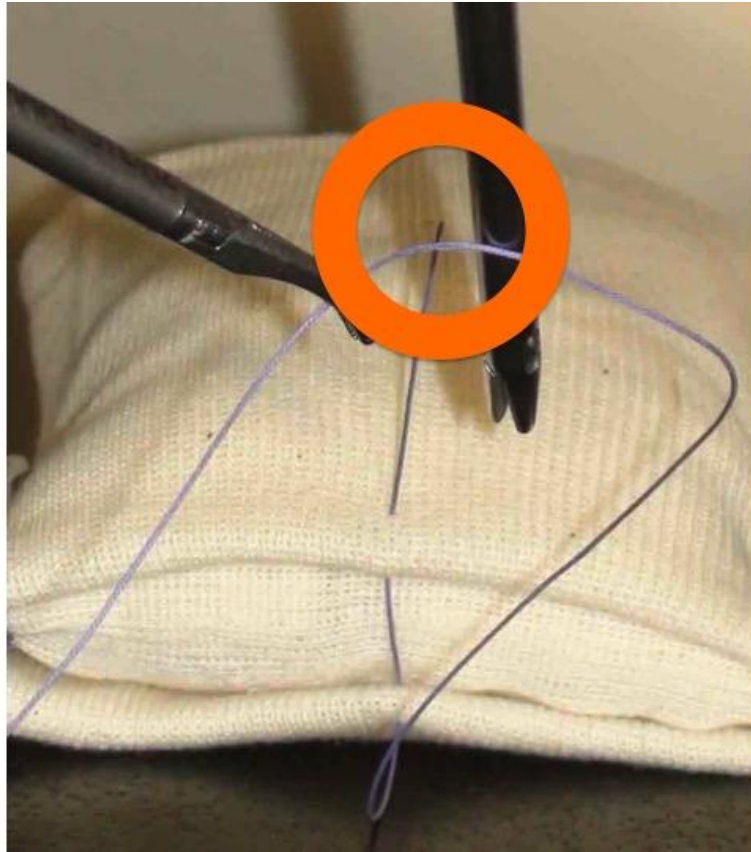
2) Move the forceps linearly to “grab” a suture or a needle.

Figure . To avoid missing the needle or suture, move the forceps linearly away from the body.



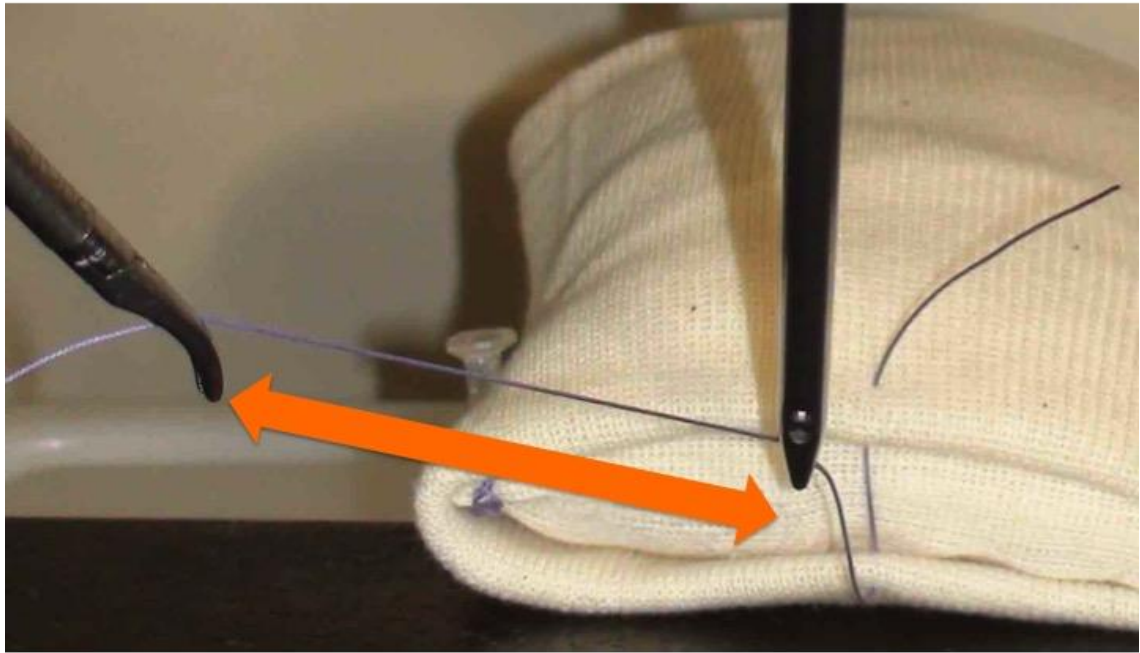
3) While “reeling” or drawing the suture, monitor the short tail more than the length of suture to avoid the short end pulling through.

Figure . Always watch the short tail while drawing or reeling the suture.



4) When reeling in the suture, pull it with a long “stride.”

Figure . Reel the suture with a long stride.



Ligation

Suture ligation, or knot tying, consists of three elements; 1) Creating a straight length of suture, 2) Throwing a loop, and 3) Securing the knot.

1) Making the suture straight

There are two ways to make a suture straight. One is the “**The Pyramid position**”, the other is the “**Mt. Fuji position**”.

There are two ways to wind a suture to create a loop for a knot. One is by using a needle driver; the other is by using a dissector.

The “Pyramid position” is suitable for winding the suture with a needle driver.

Align the suture and needle holder and wind the suture by twisting the needle holder with the straightened thread as the axis.

Mt. Fuji position is optimal for winding a loop with a dissector.

Maintain the angle between a needle holder and the suture, and use the dissector or forceps to wind the thread around the needle holder.

Figure . The Pyramid position.




Figure . Winding the loop.



Figure . Mt.Fuji position.

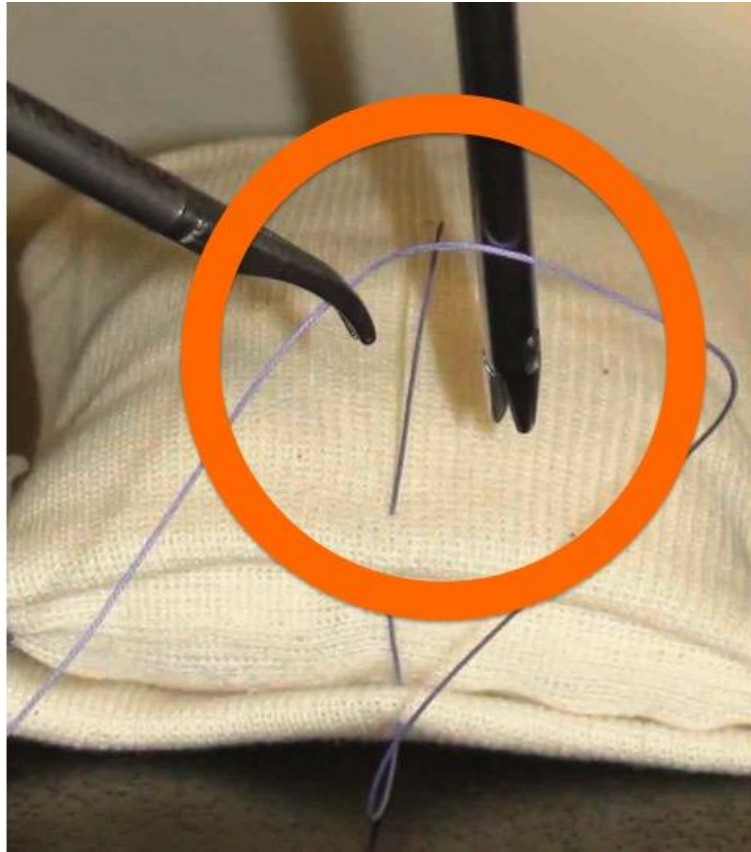


2) *Winding the loop*

An ideal loop is created by taking a suture with a dissector and looping the suture around the needle driver. This is ideally achieved with a short tail and a big loop.

Daily training of circulating a dissector clockwise and counterclockwise alternately more and more quickly without scratching the instruments together will train the surgeon to throw elegant knots.

Figure . Make a throw around the shaft of the needle driver just in front of a short tail.



3) *Tighten the knot firmly*

Feel the haptic sensation and use a sliding knot and surgeon's knot effectively.

Handling the needle

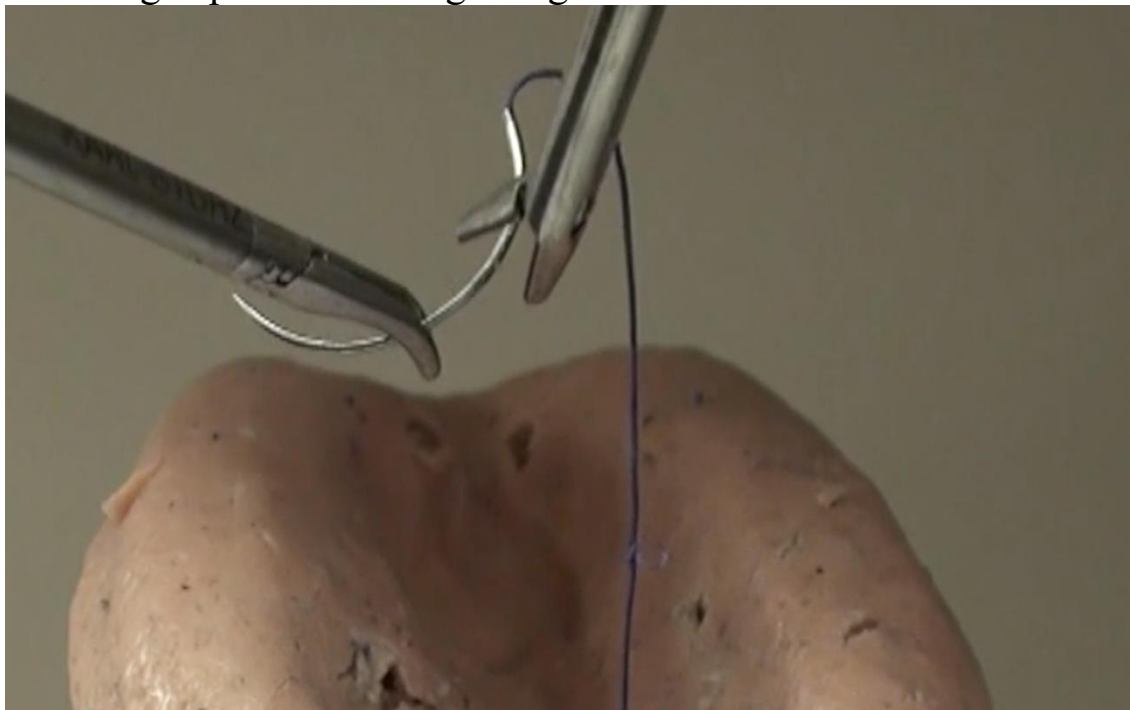In laparoscopic surgeries, Surgeons must be able to correctly grasp a needle at a perpendicular angle. Correct and quick grasping techniques are needed.

Grasping techniques

Direct

One can change the direction of a needle by using a dissector to adjust it and regrasping the needle with the needle driver. Use both instruments to correctly adjust the angle to 90 degrees.

Figure . Changing the angle of the needle may be done by rotating the wrist to grasp at an ideal right angle.



“Dancing Needle”

1. Hold the thread 15 mm above the swedge of the needle with a needle driver.
2. Grasp the middle of the needle gently with a dissector.
3. Pull the thread by the needle driver to adjust the needle to the

proper angle.

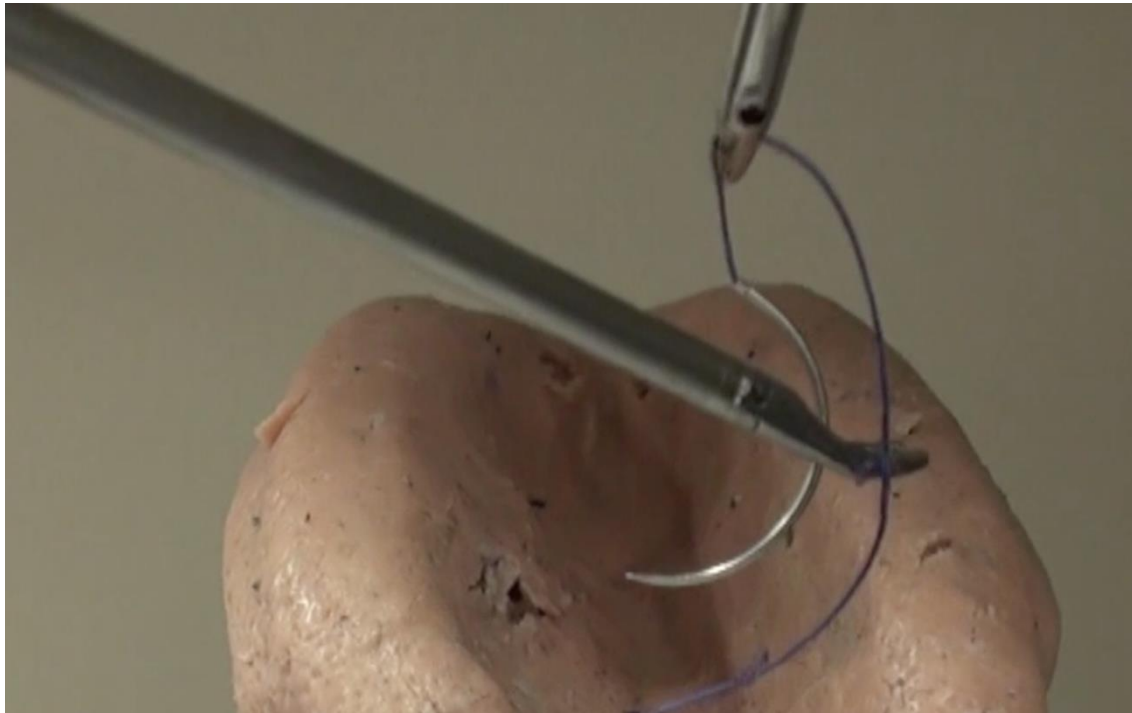
Figure . Hold the suture 15 mm above the swedge of the needle with a needle driver.

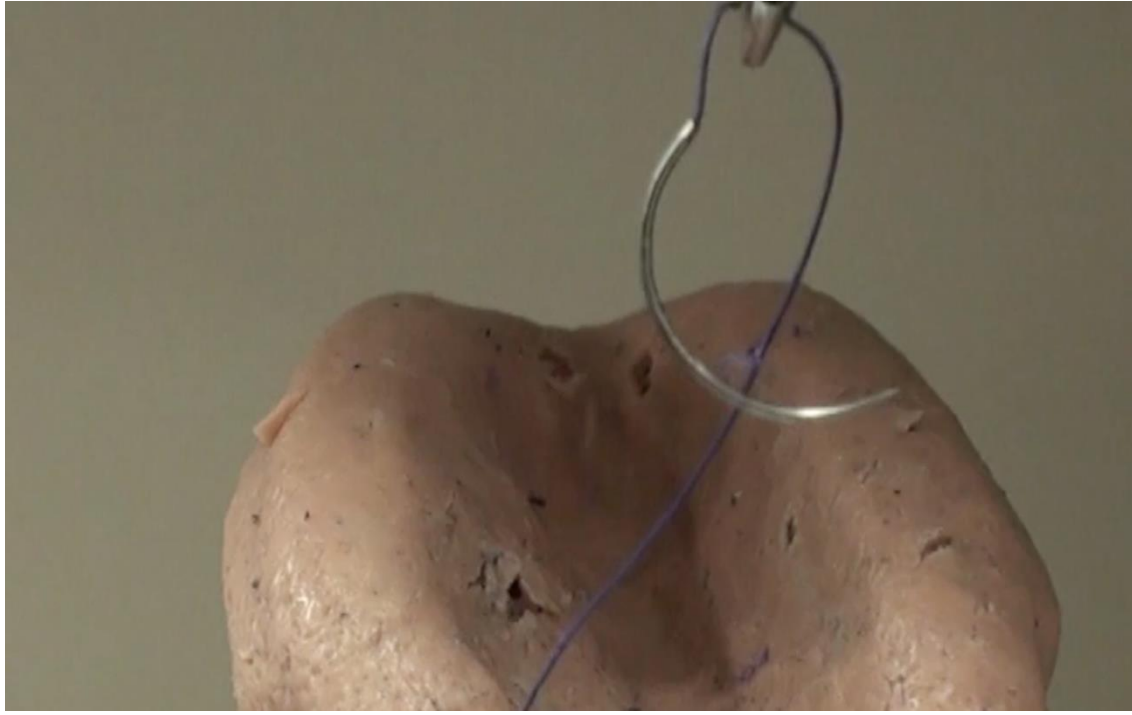

Figure . Grasp the middle of the needle gently with a dissector.

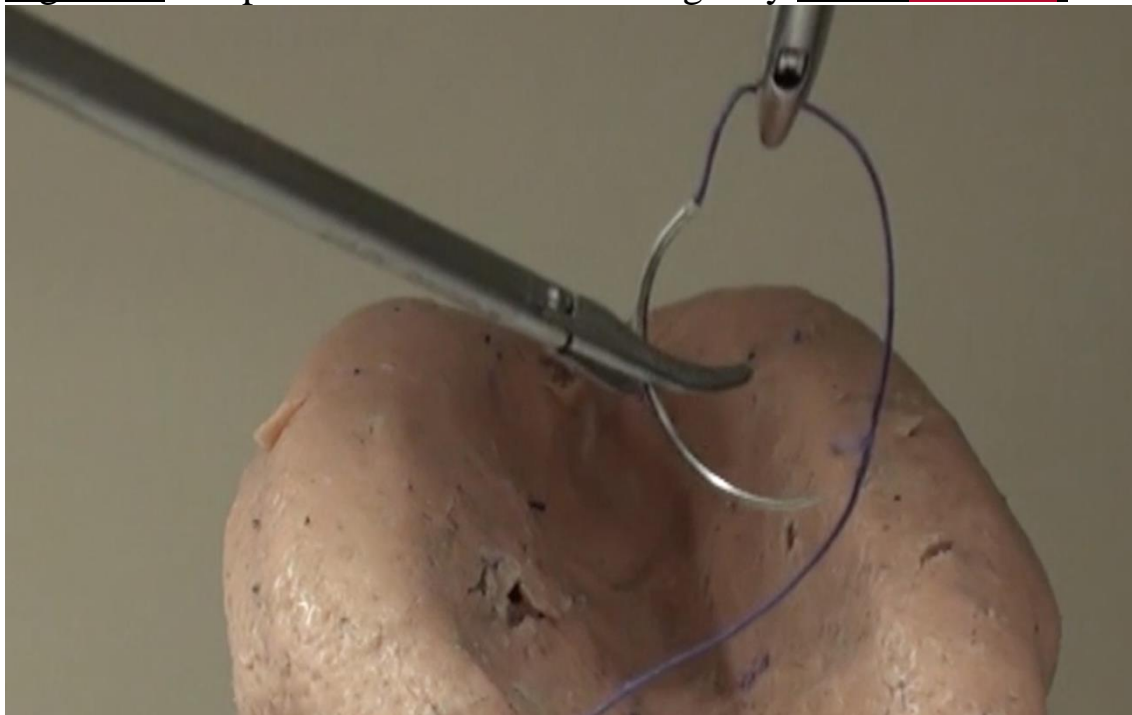

Figure . Pull the thread by the needle driver to adjust the needle to the proper angle.



Dancing Needle 2

1. Hold the suture 15 mm above the swedge of the needle with a dissector.
2. Grasp the needle gently near the tip with a needle driver.
3. Using the dissector, pull the suture to adjust the angle of the needle the desired angle.

Figure Hold the suture 15 mm above the swedge of the needle with a dissector.

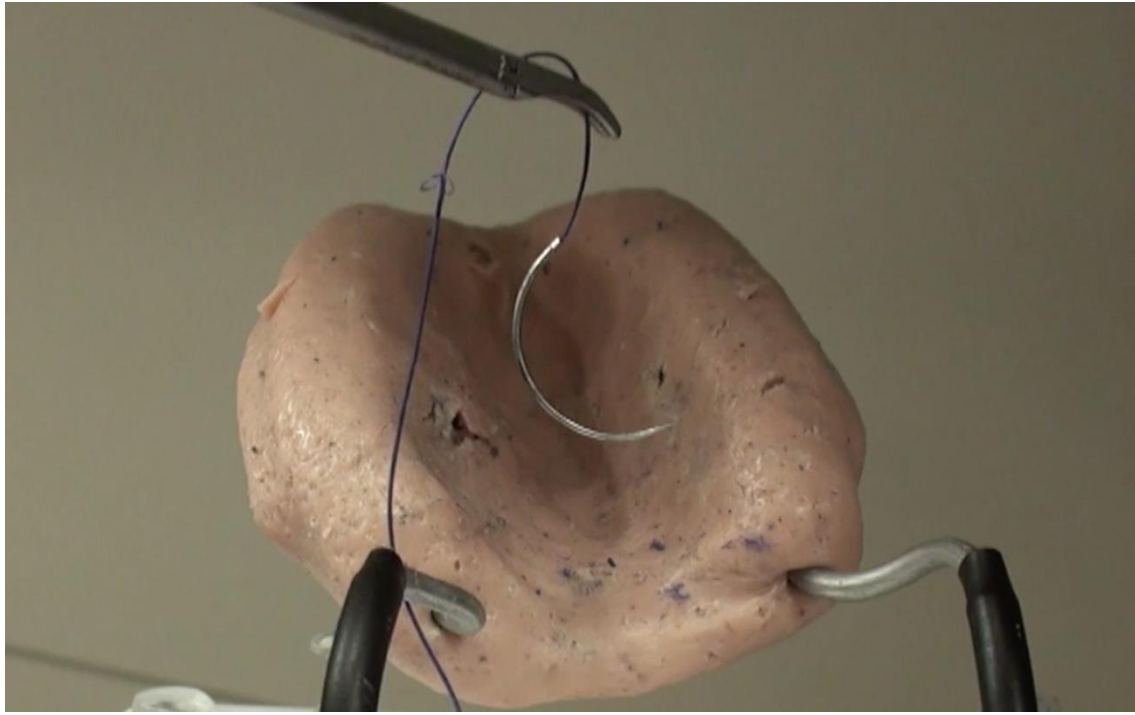

Figure. Grasp the needle gently with a needle driver.

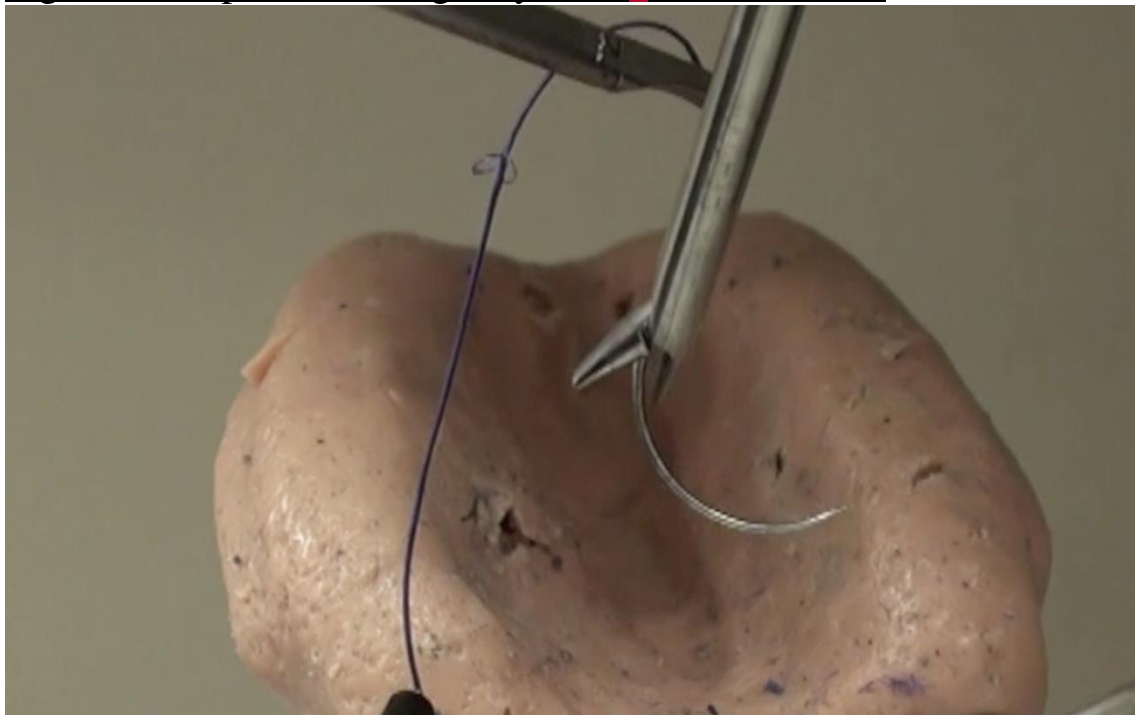
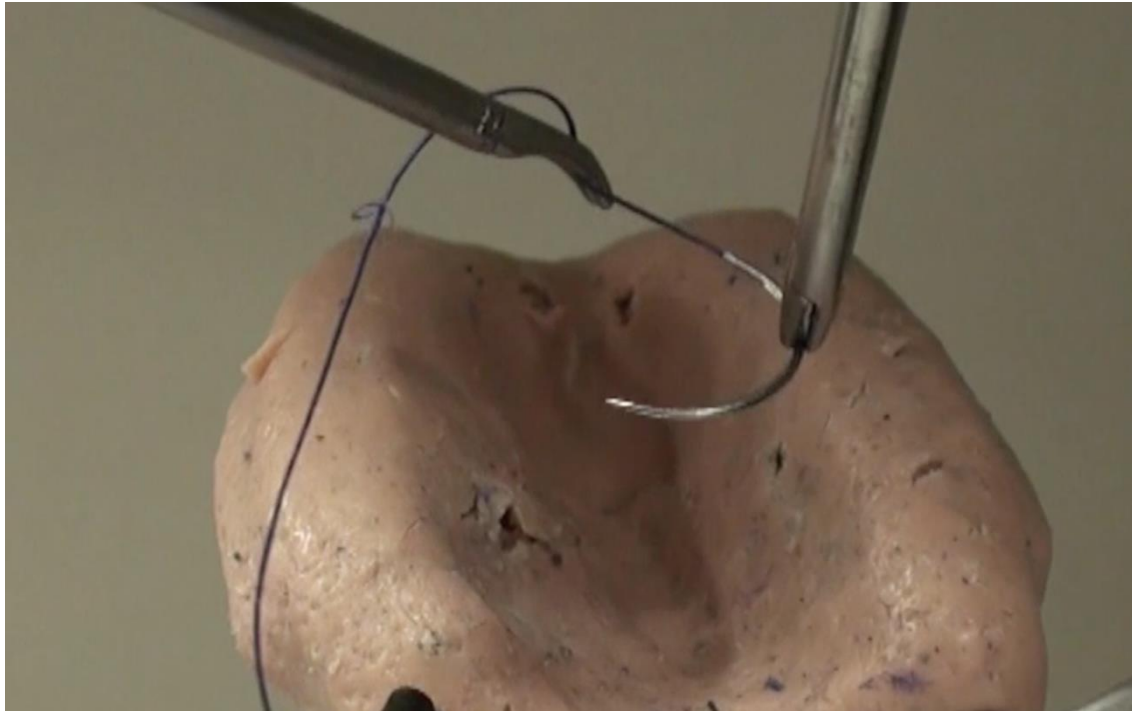


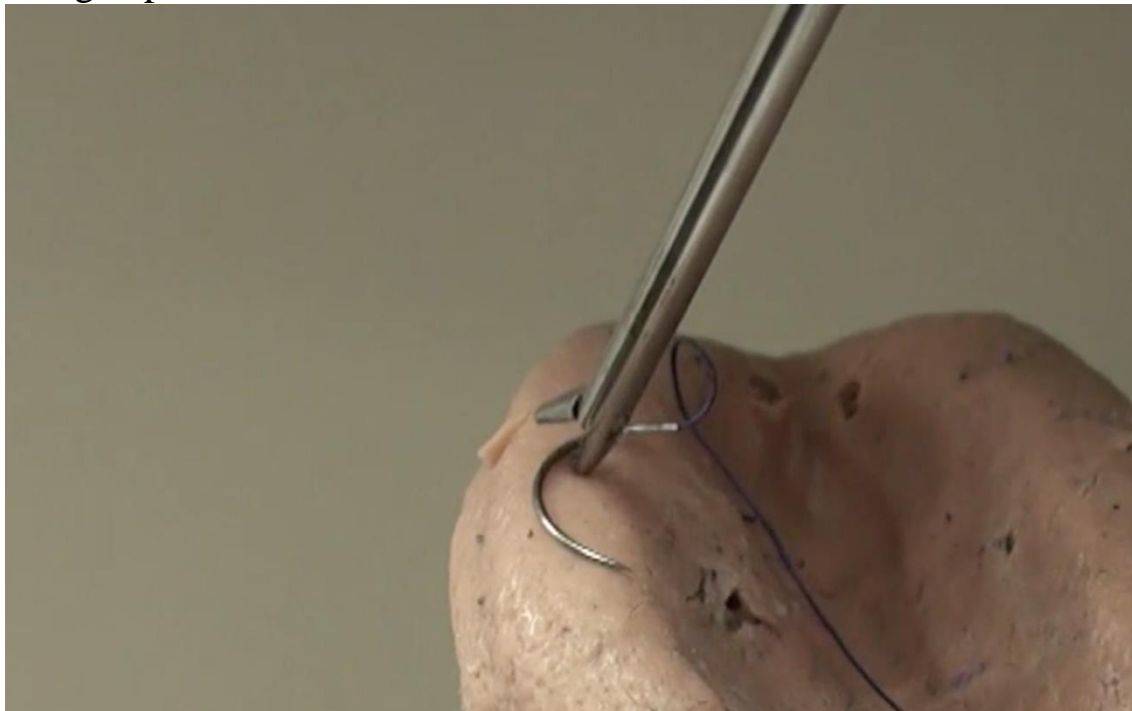
Figure Pull the suture with the dissector to adjust the angle of the needle.

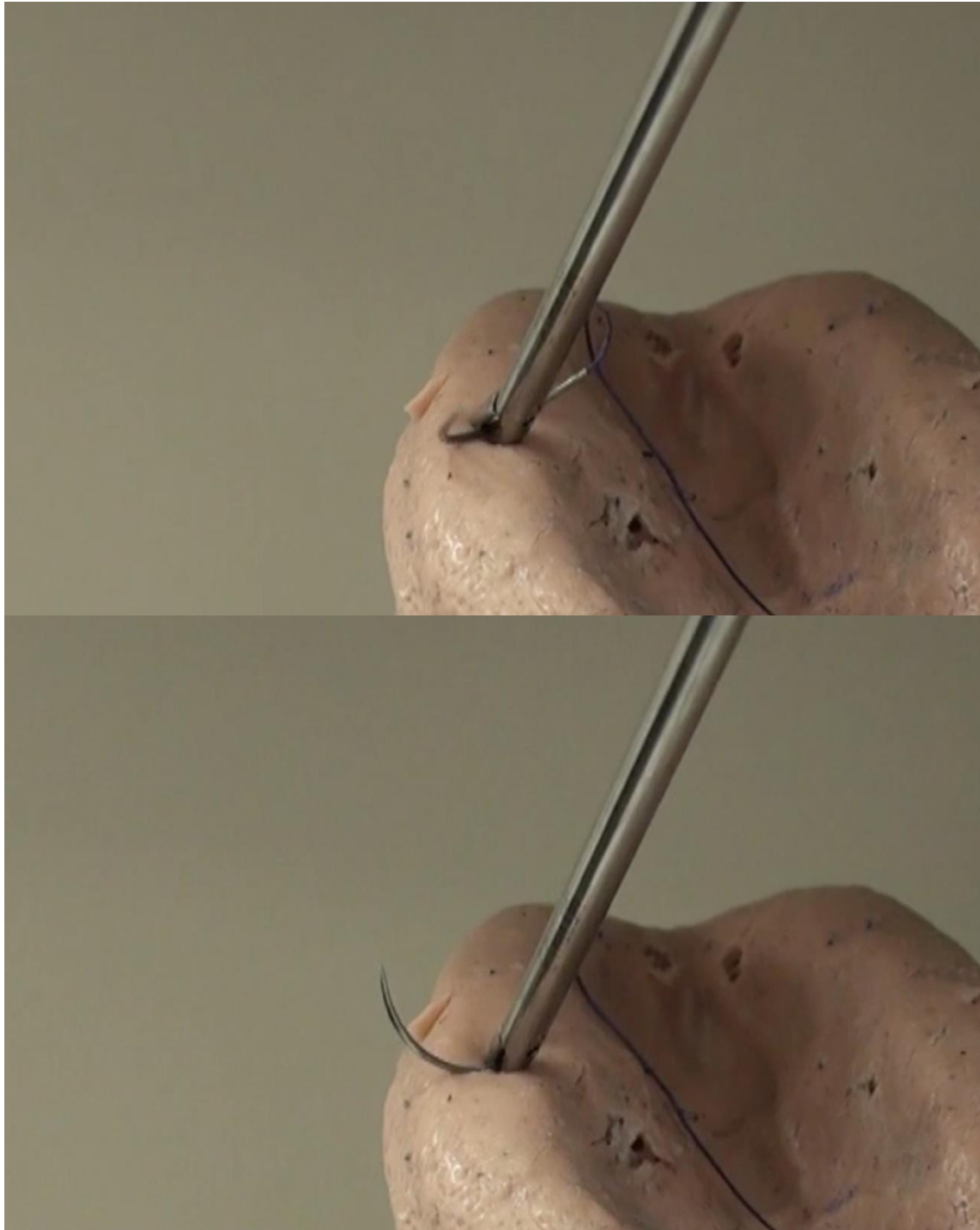


“Wake me up”

Insert the needle driver with its tip open between a needle and the tissue below. Then, close the tip slowly while pushing the tissue away from the needle.

Figures Gently push the underlying tissue with an open needle driver and grasp the needle.

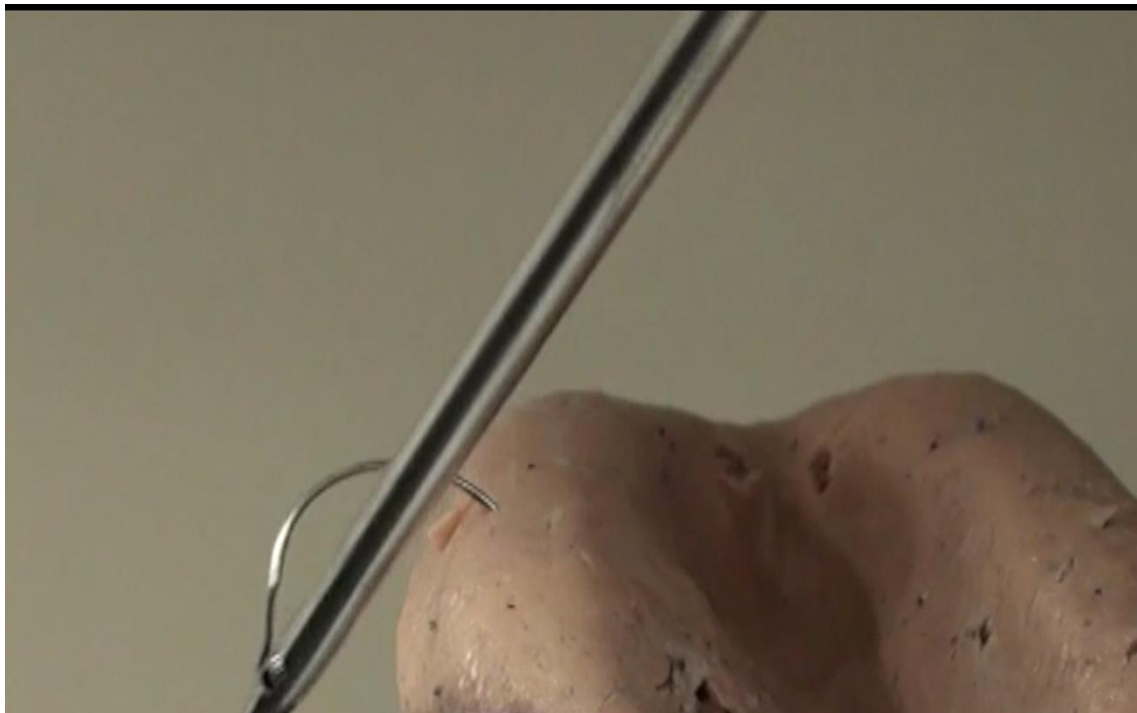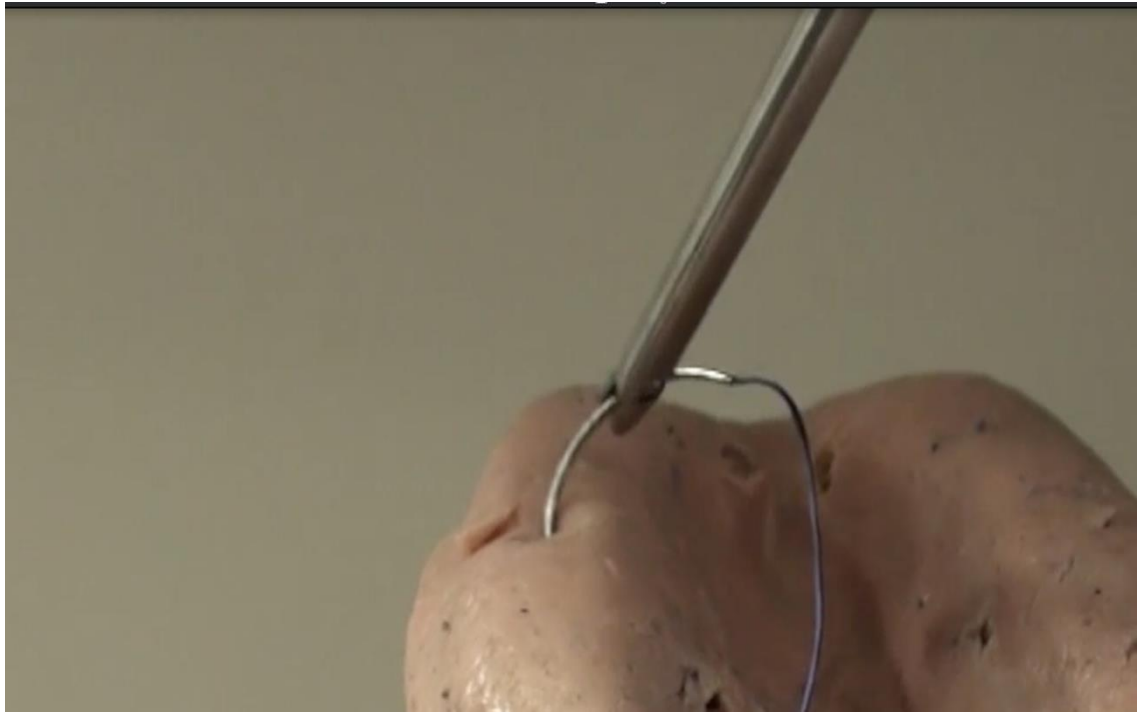


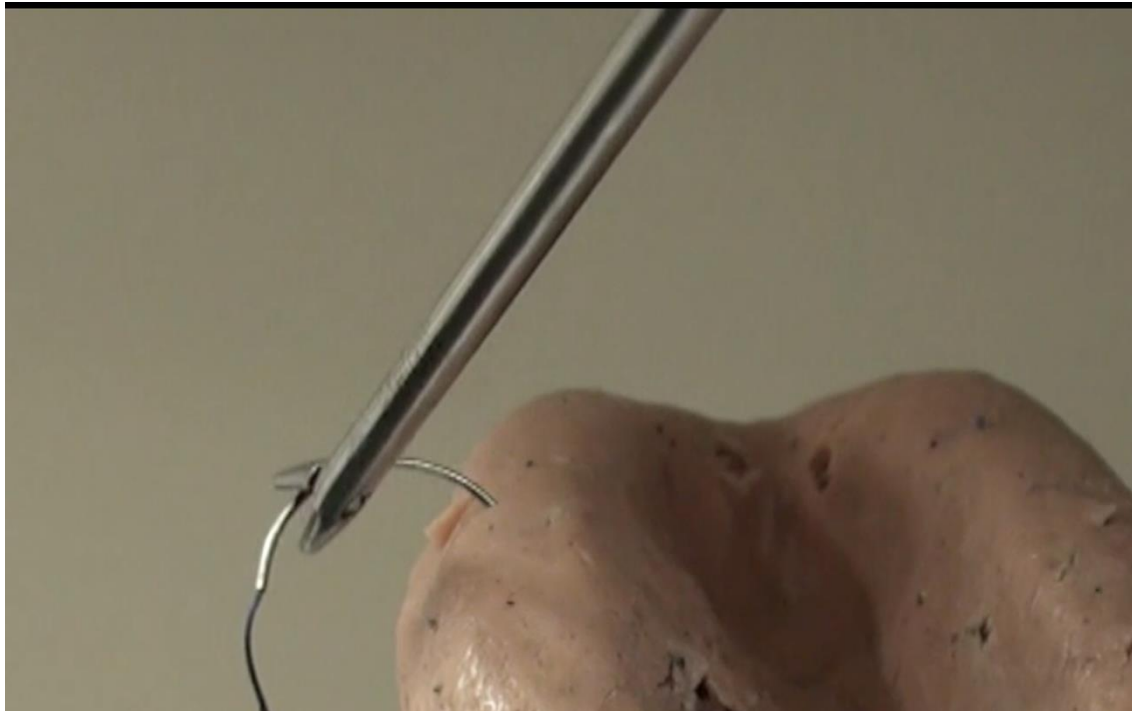


Stab

Stick a needle into non-vascular area of peritoneum to change the direction of needle by drawing the suture to adjust the angle.

Figures Gently stick the needle into a non-vascular area to adjust the angle of the needle.

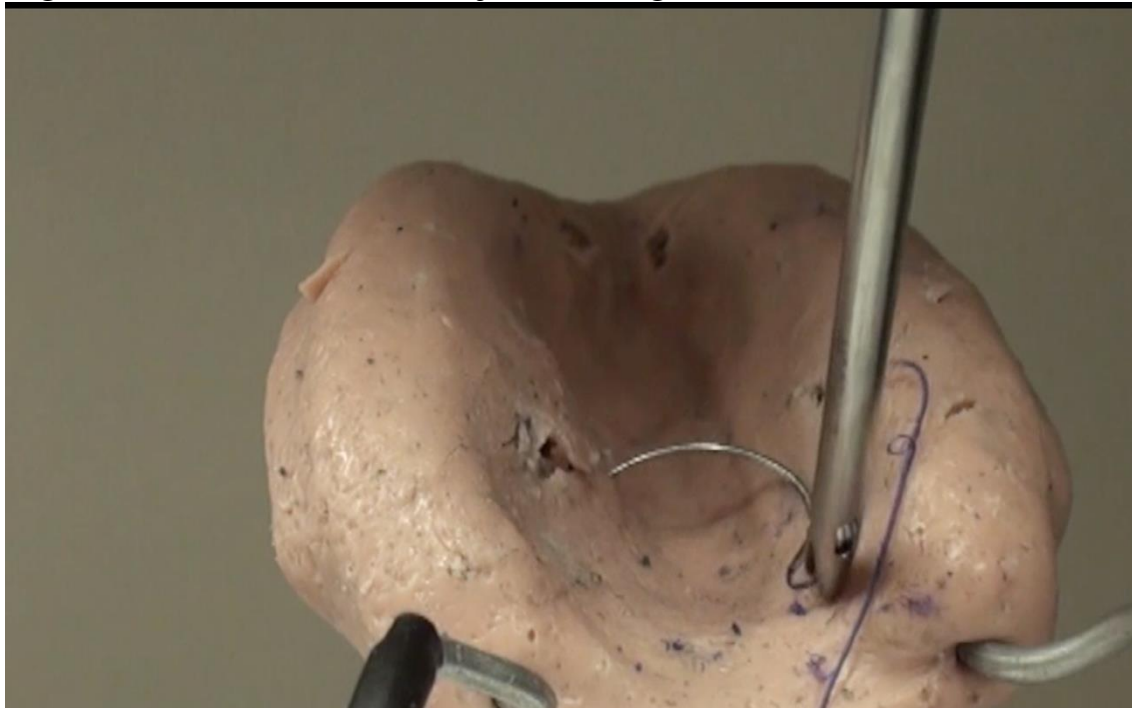




“Roll”

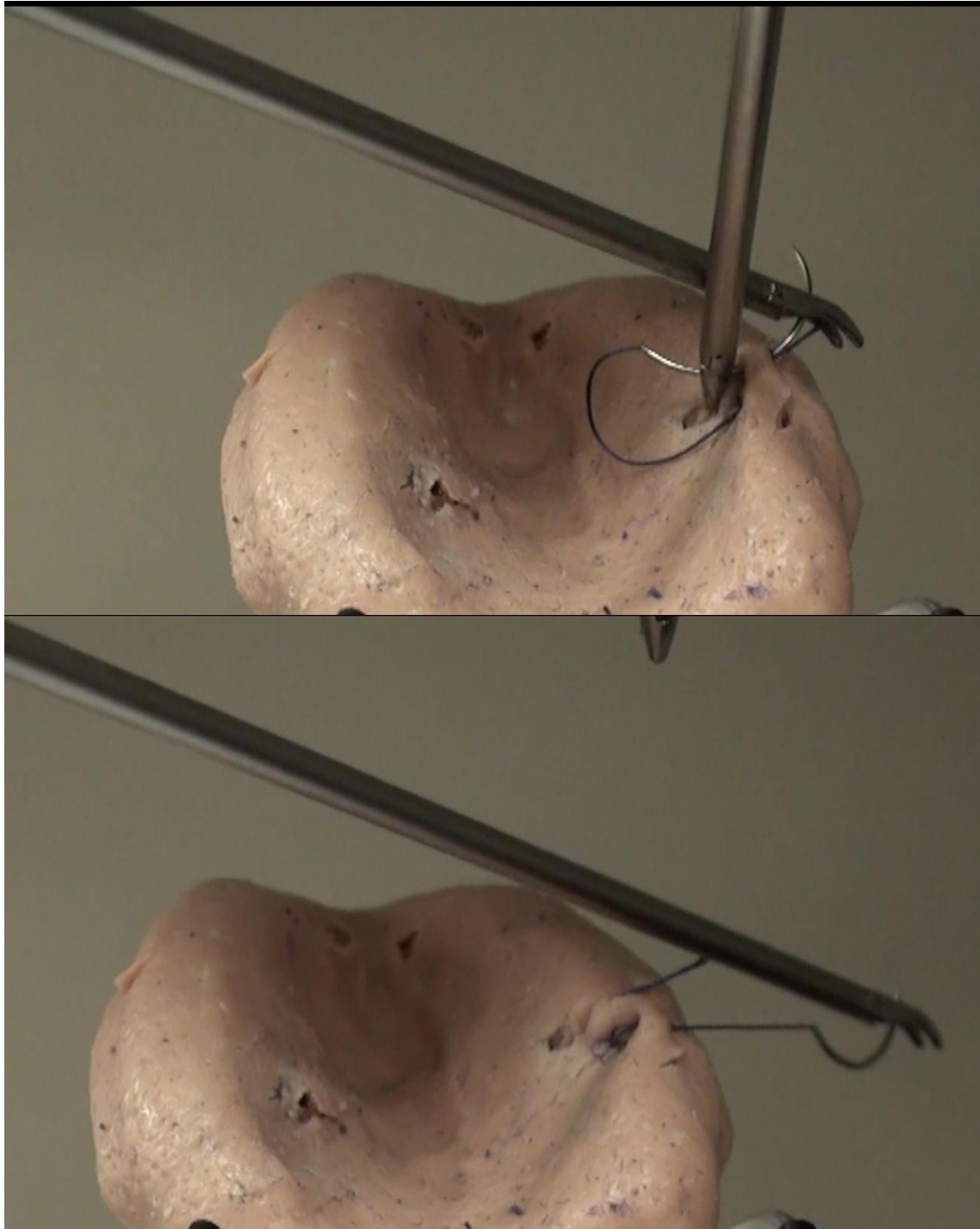
Pick up the suture with the needle driver and roll it to adjust the needle to the desired right-angle position.

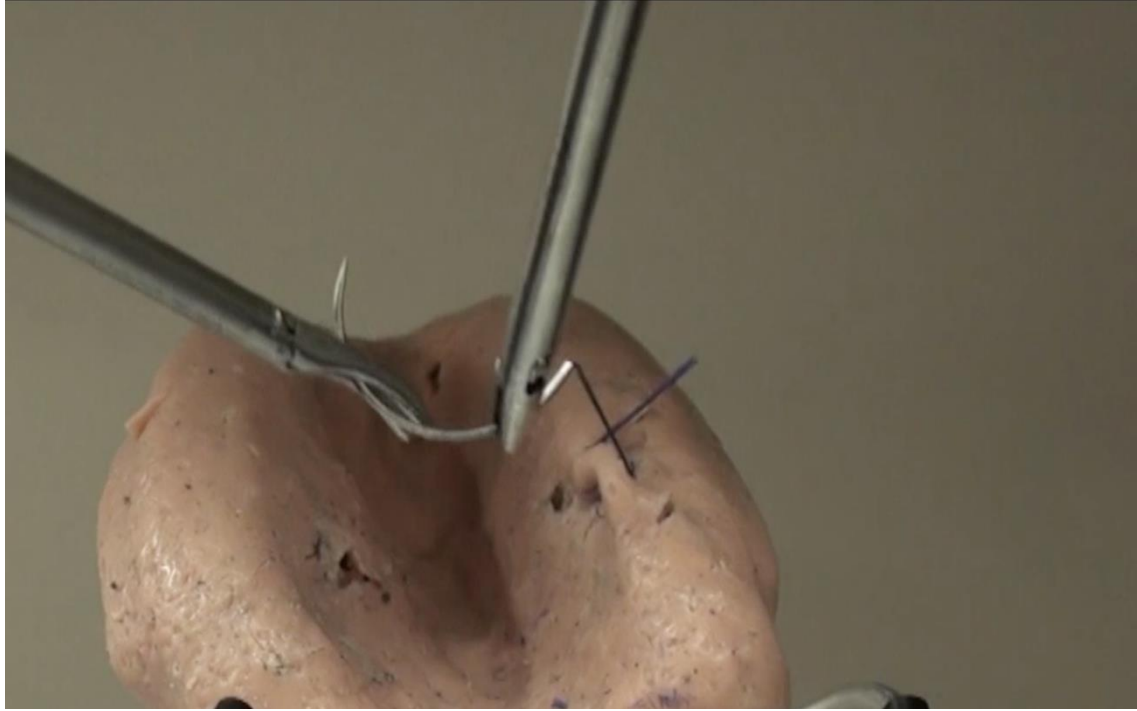
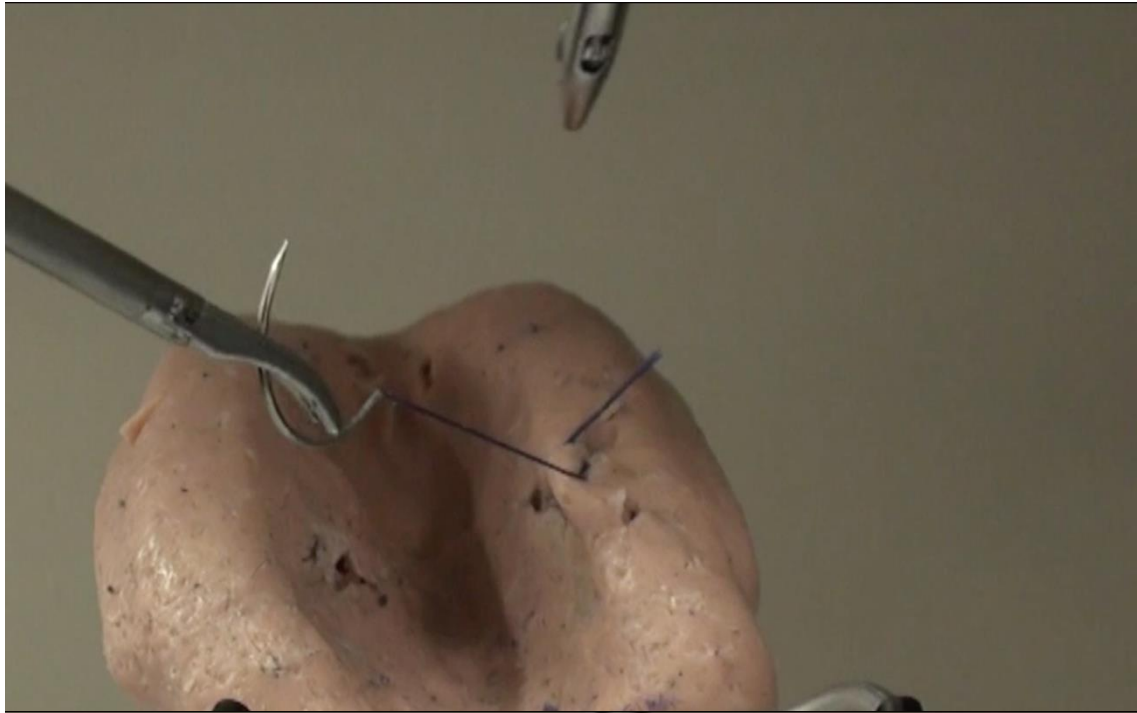
Figure Roll the suture to adjust the angle.



Swallow Flight

Change the direction of the needle by swinging the dissector holding the needle





Seven Techniques for Laproscopic Surgeon's Knot

The ***Surgeon's Knot*** is one of the most important techniques for ligating tissues securely. After the first loop is thrown, a second loop is wound in the same direction before grasping the tail and securing the knot.

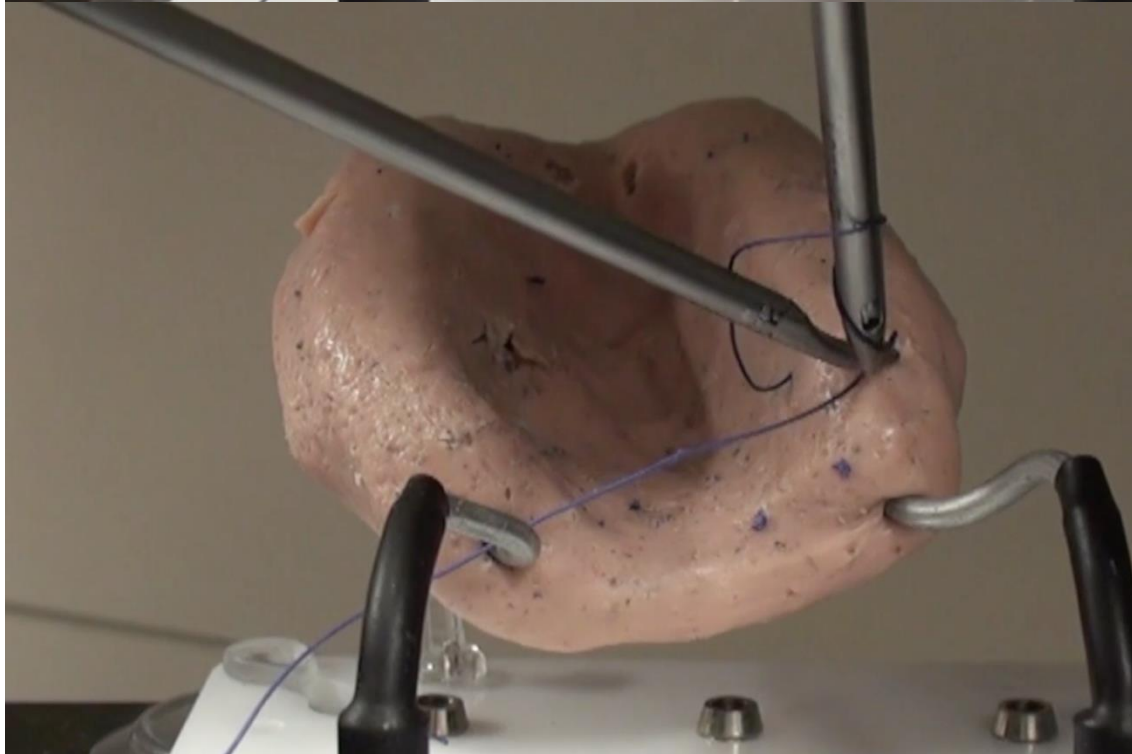
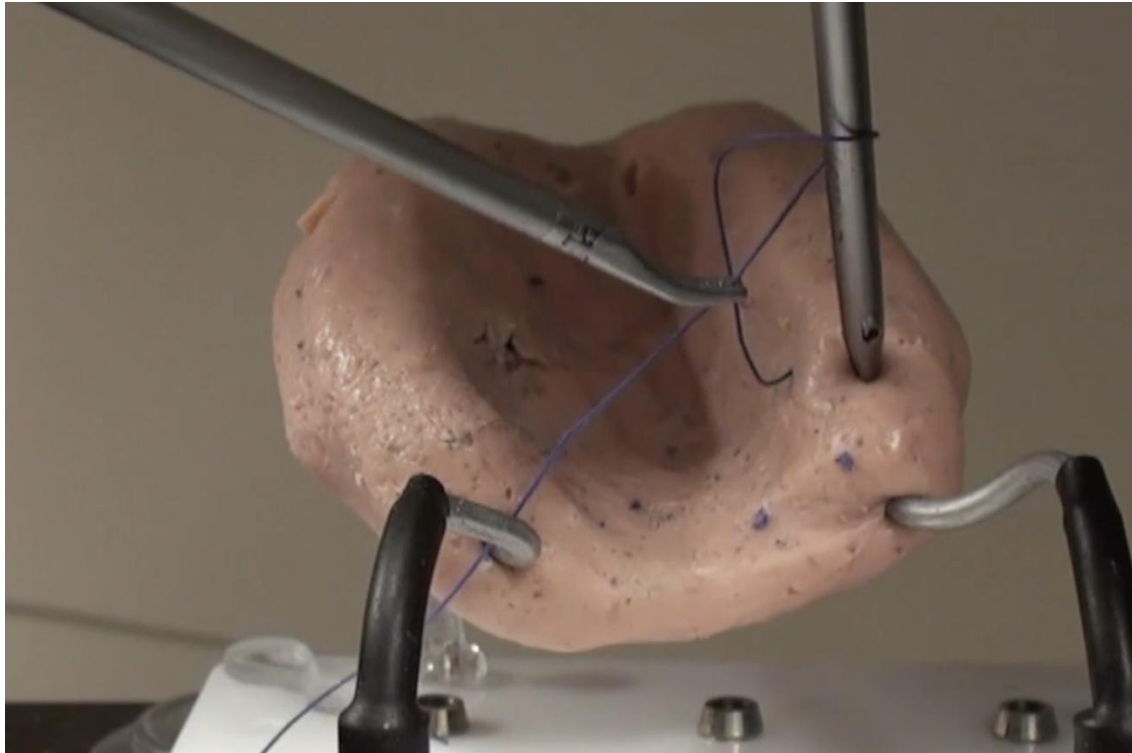
A **square knot** is a double loop in which the first throw is around a needle-driver's shaft clockwise and the second throw around the needle-driver's shaft counterclockwise. This creates a knot that allows for sliding versatility along the suture.

Below are seven techniques for laparoscopic surgeon's knots. We recommend mastering all of the techniques to add depth of security for complex cases. Each of the following techniques aids the surgeon in skillfully completing the second loop of a surgeon's knot.

“Moon walk”

After the first loop, touch the tip of the needle driver onto the tissue so the suture will not slip out while winding the second loop.

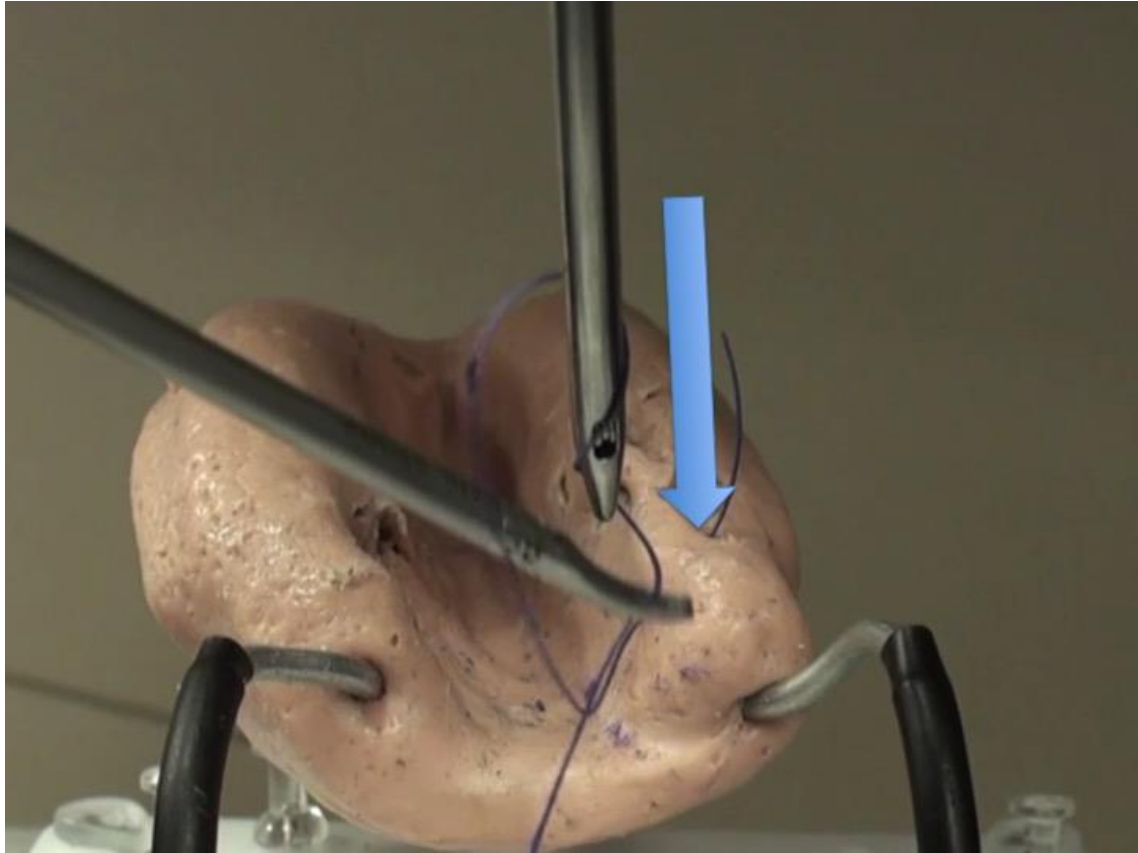
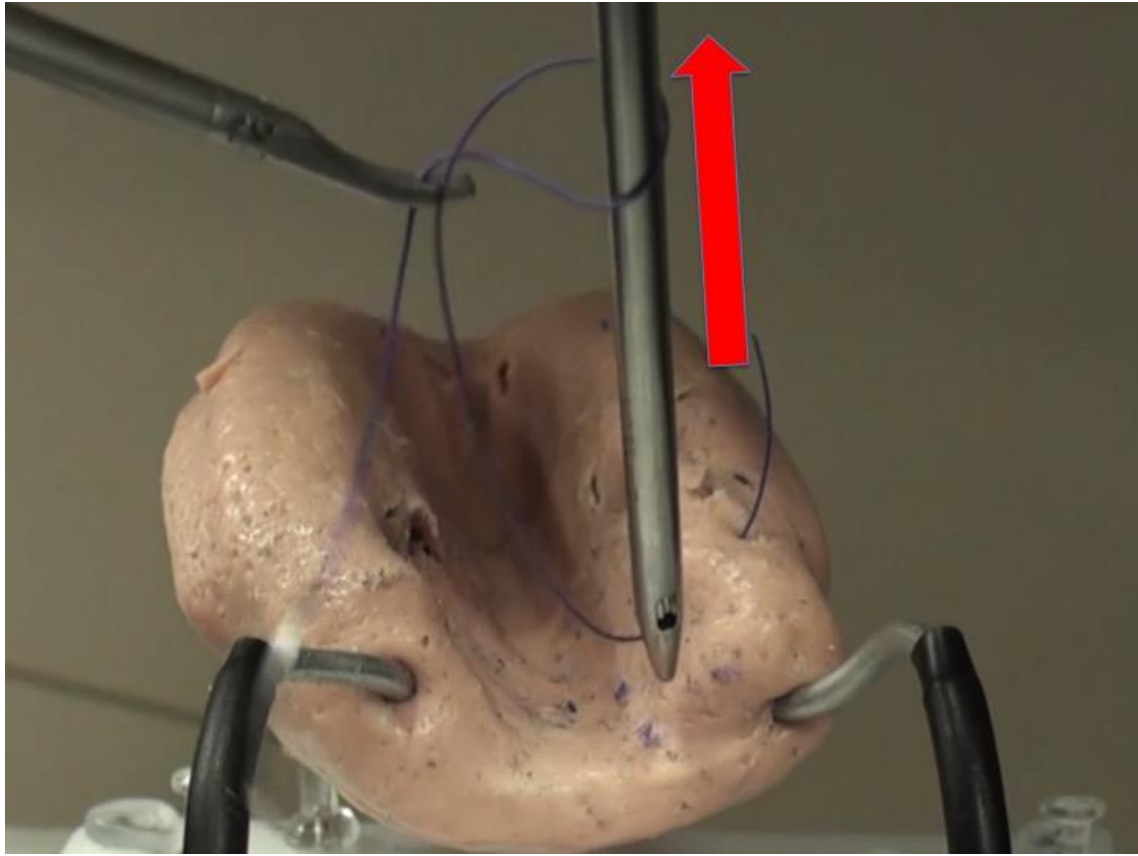
Figures Touch the tip of the needle driver onto the tissue so the suture does not slip while winding the second loop.



Barber King

After making the first loop around the grasper's shaft, lift the first loop up and drop the loop down to make a second throw.

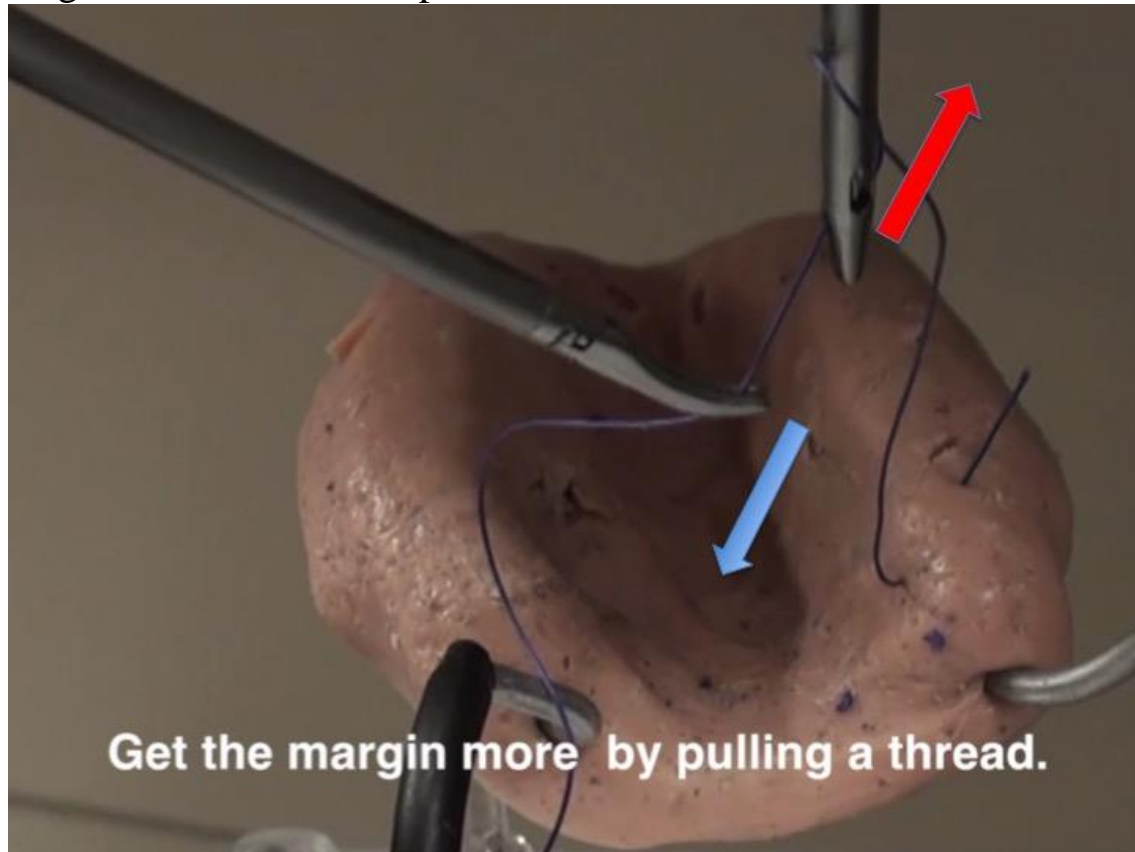
By lifting the loop up and dropping down the grasper, you can make it stay to make a space for the second loop.



“Give me some more”

After making the first loop, grasp and pull the suture with the needle-driver to make enough length for the second loop.

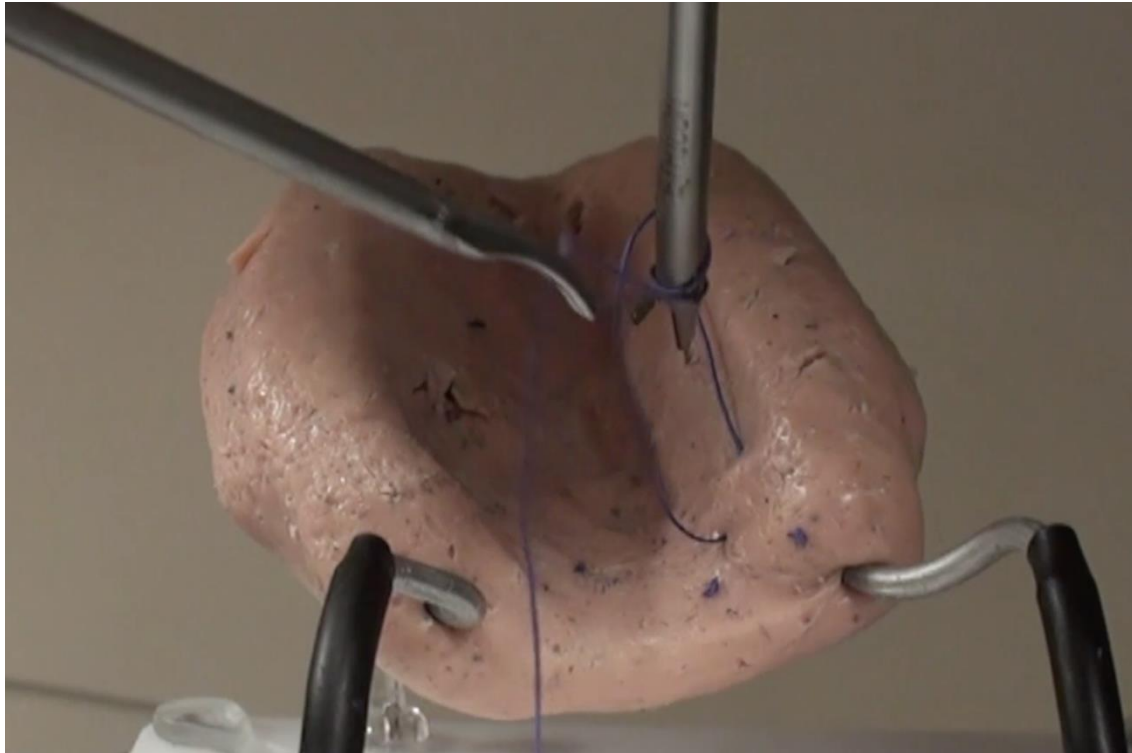
Figure Grasp and pull the suture with the needle-driver to make enough length for the second loop



“Thumbs up”

After the first loop around the needle-driver’s shaft, open the tip of grasper so the suture cannot slip down, and make the second loop.

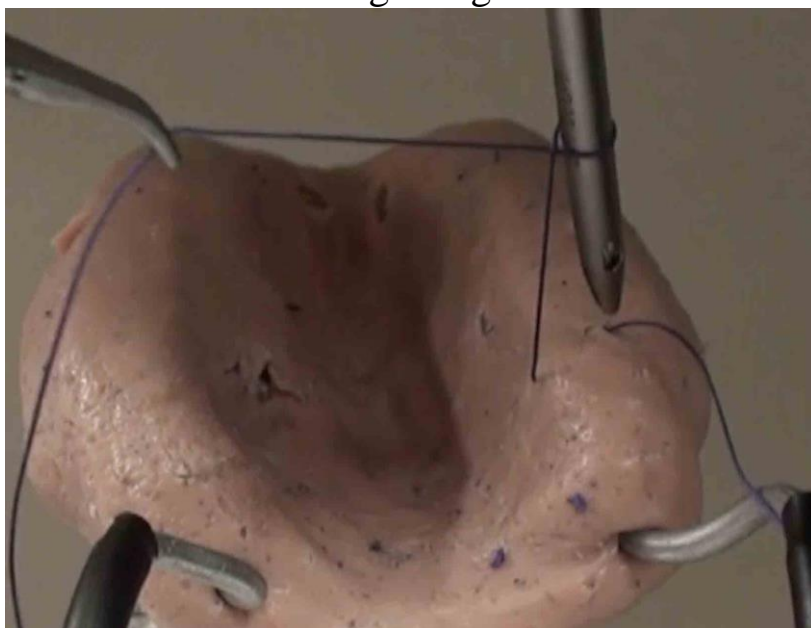
Figure Open the tip of grasper so the suture cannot slip down, and make the second loop.

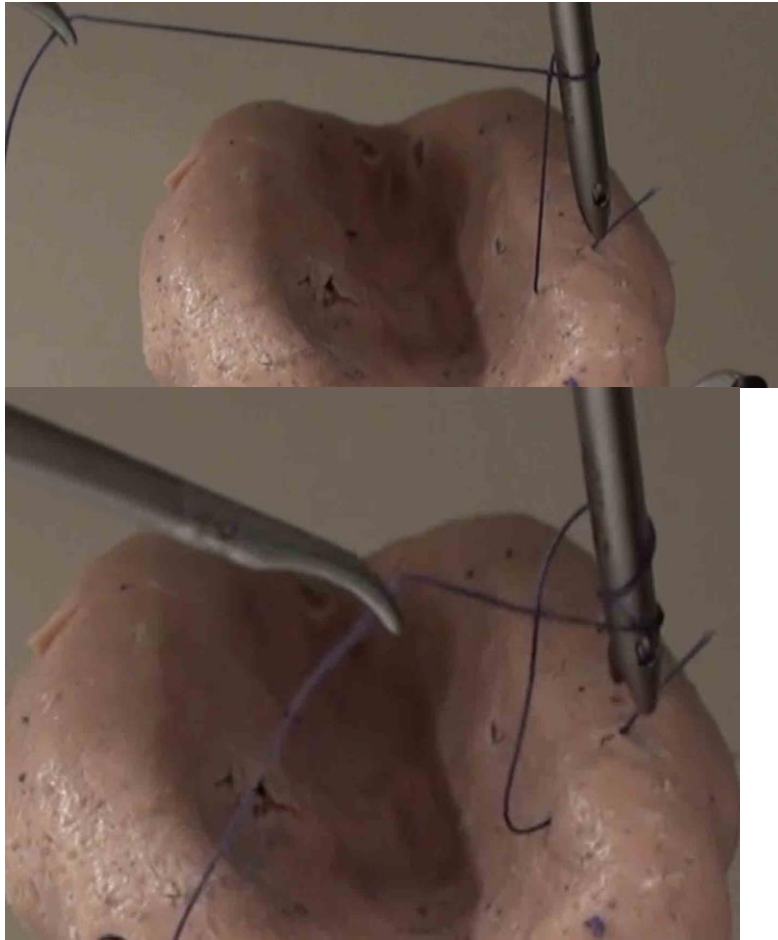


“Funky fishing”

After the first loop around the needle driver’s shaft, reel the suture with the dissector using the needle-driver as a fulcrum to make enough length for the second loop.

Figures Reel the suture with the dissector using the needle-driver as a fulcrum to make enough length for the second loop.

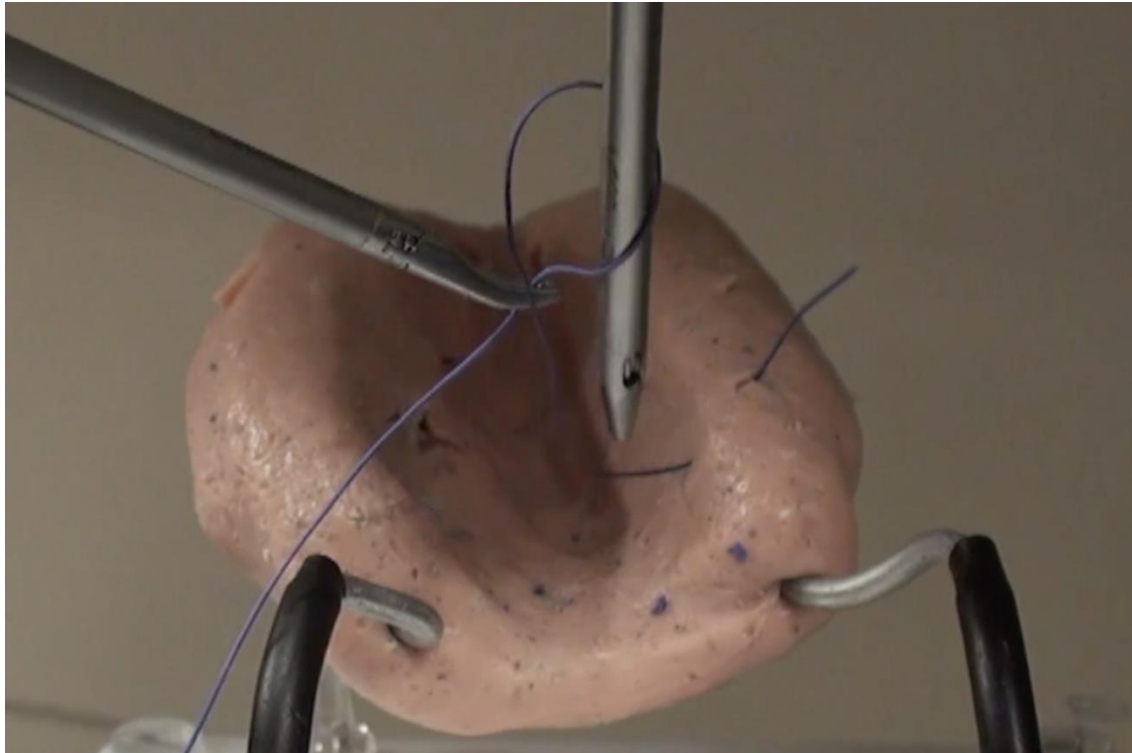




“Screw Driver”

Straighten the suture in the **Pyramid style** (see the previous section) and throw the thread by moving the needle-driver.

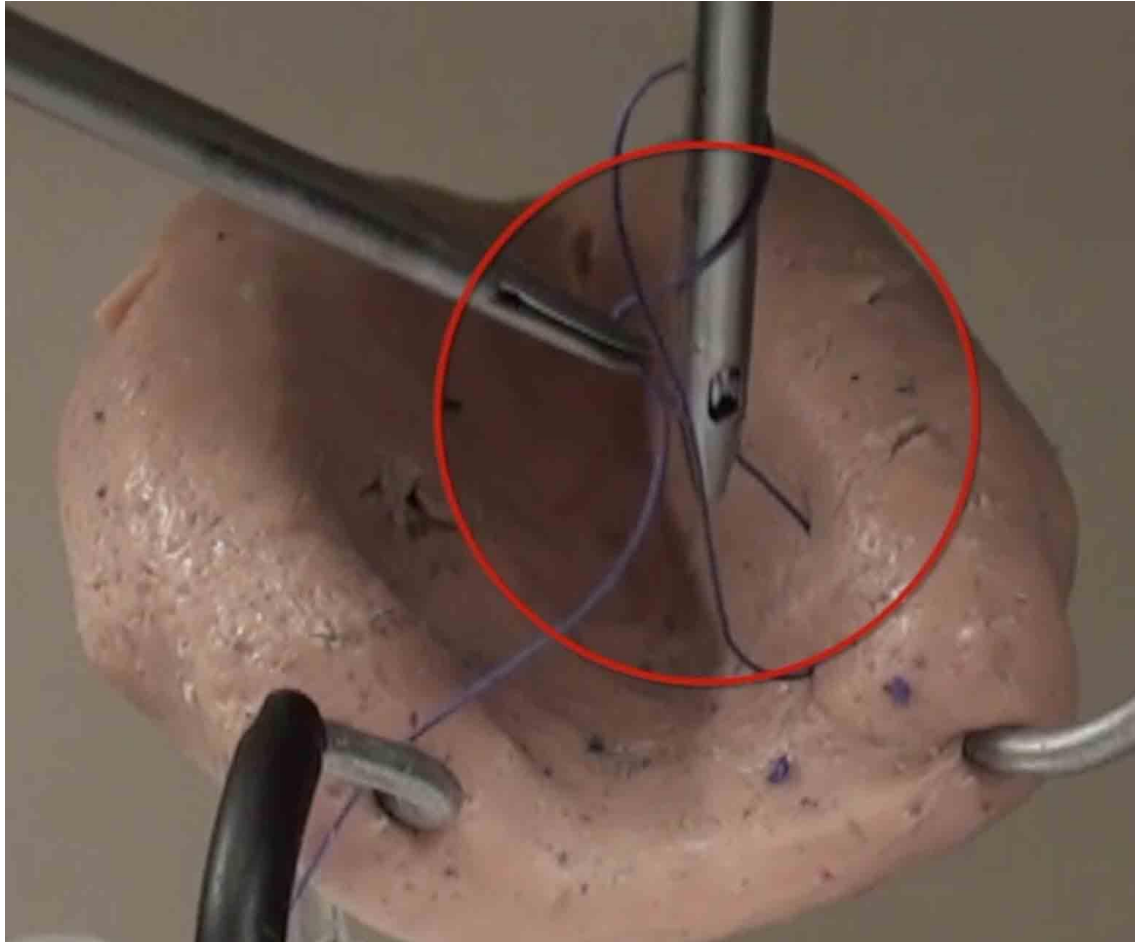
Figure Coil the suture around the grasper.

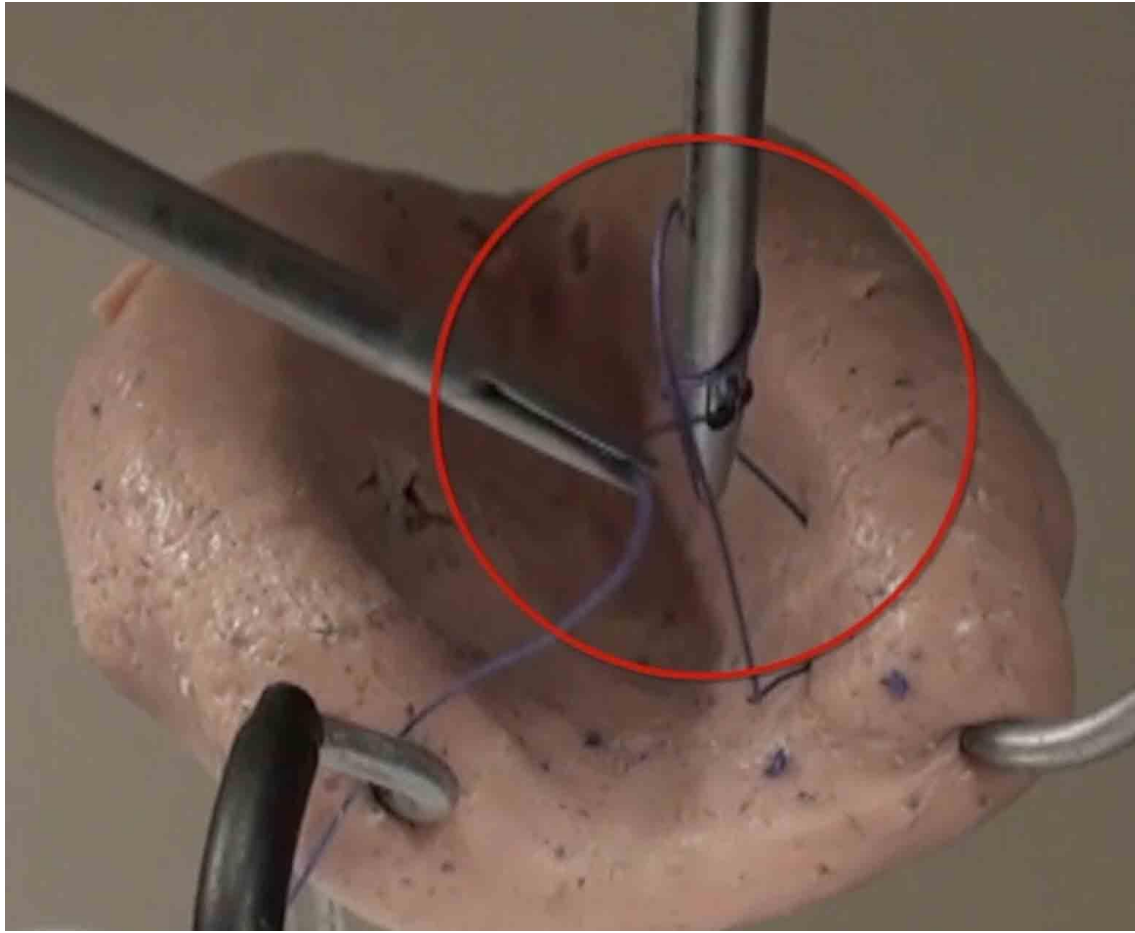


“Twisting the night away”

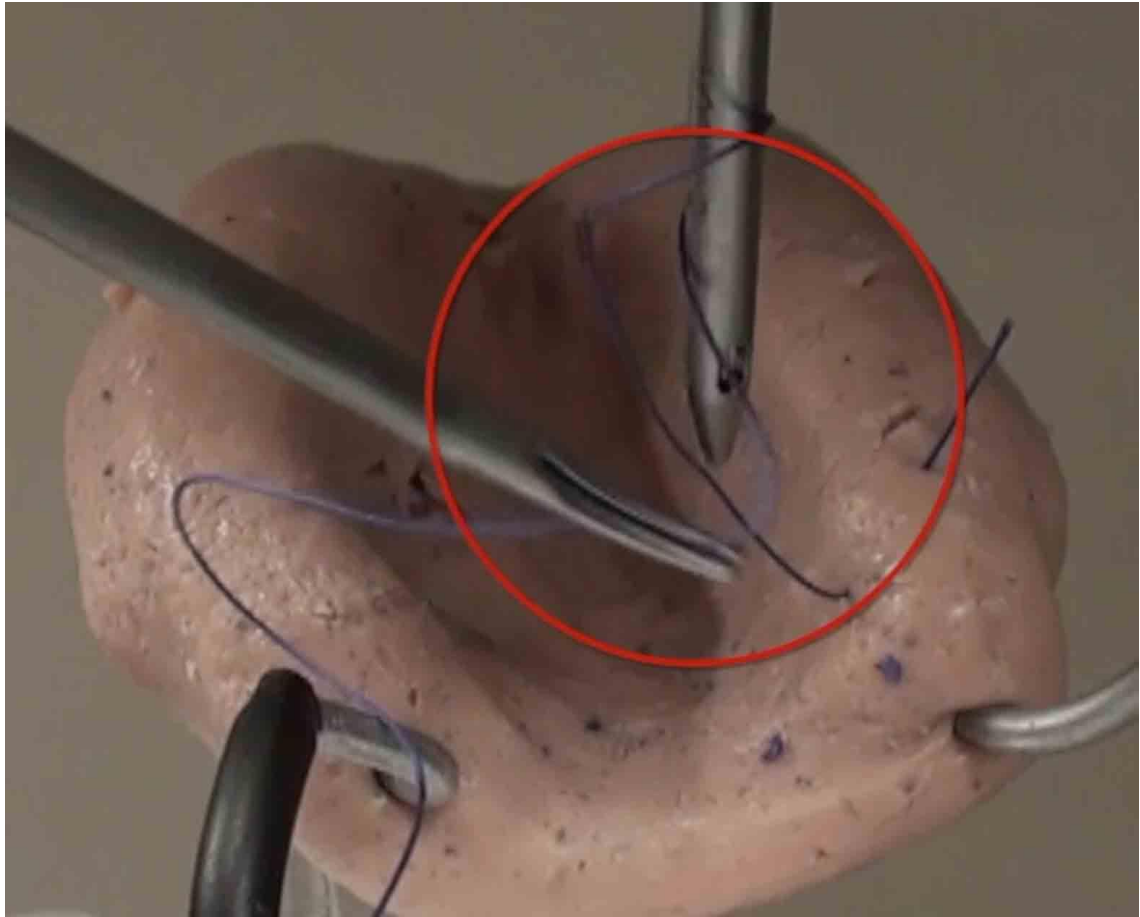
After throwing the first loop, twist the tip of a dissector to easily make the second loop.

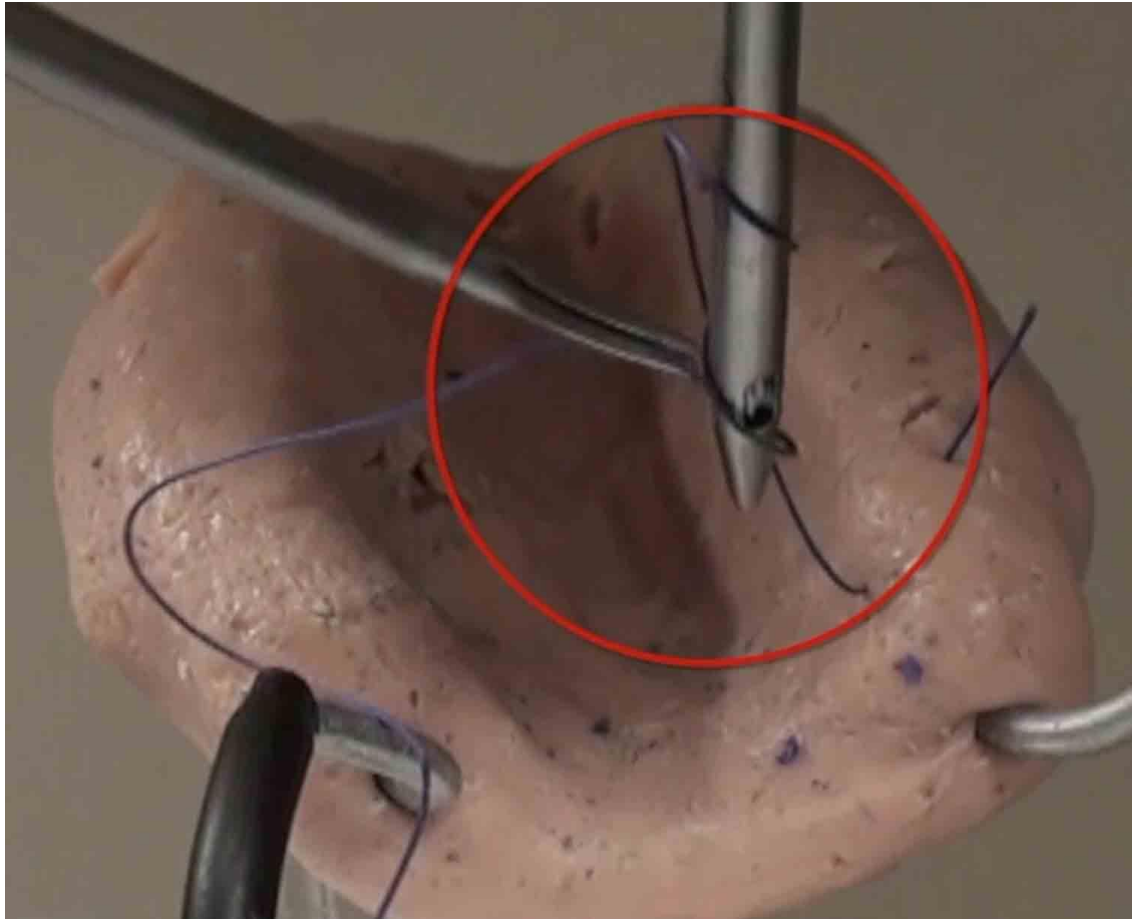
Figures Rotate the dissector to more easily throw the second loop.
(Clockwise)





(Counterclockwise)






Sliding Knot Techniques

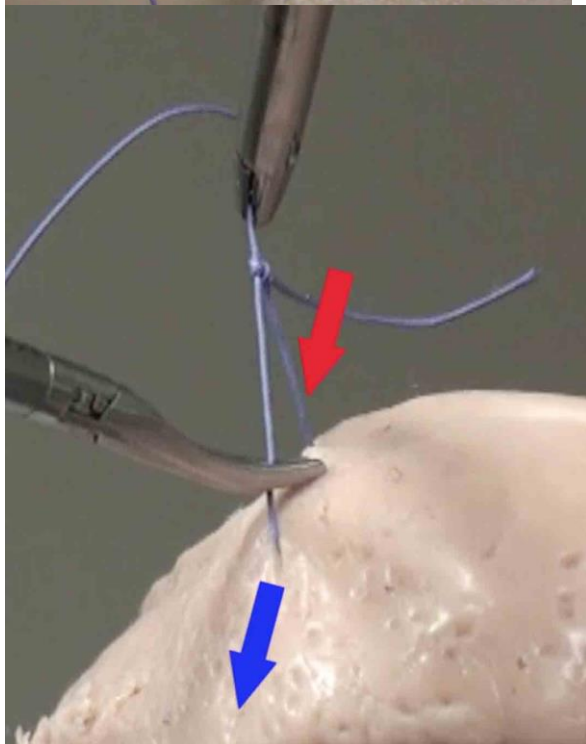
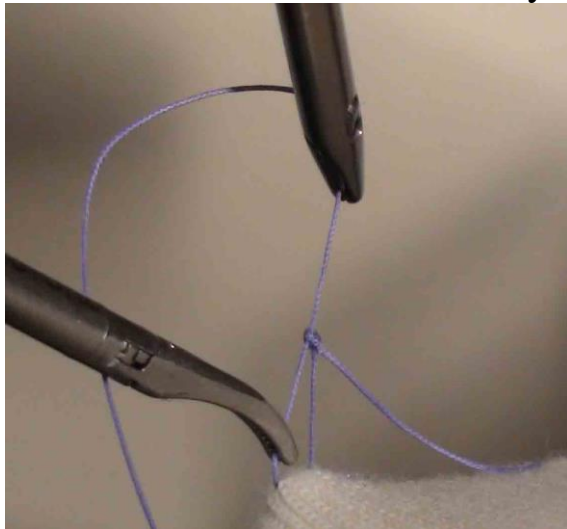
“Sliding Knot” is a convenient method for ligating tissues securely by sliding the knot along the suture. Before securing the knot, make a square knot as shown above.



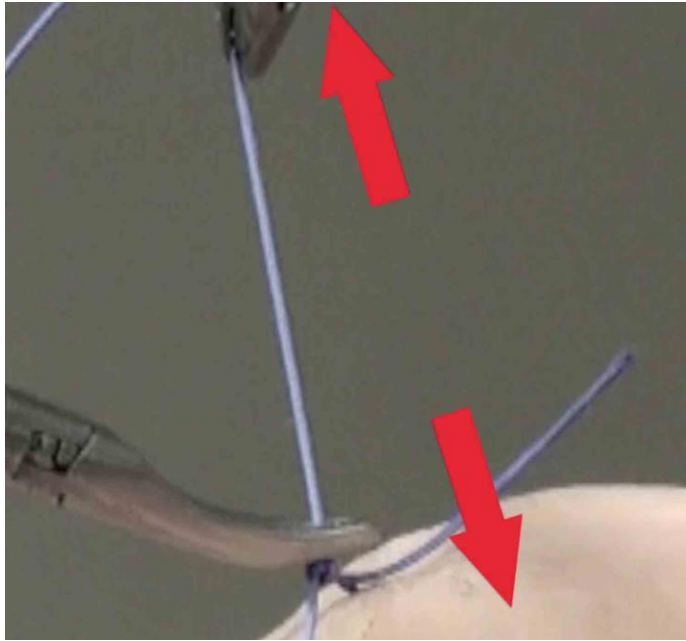
Make a square knot (as shown above).



2 Release the lock of the knot by a dissector.



3 Slide the knot to the ligation point and secure the tissues.

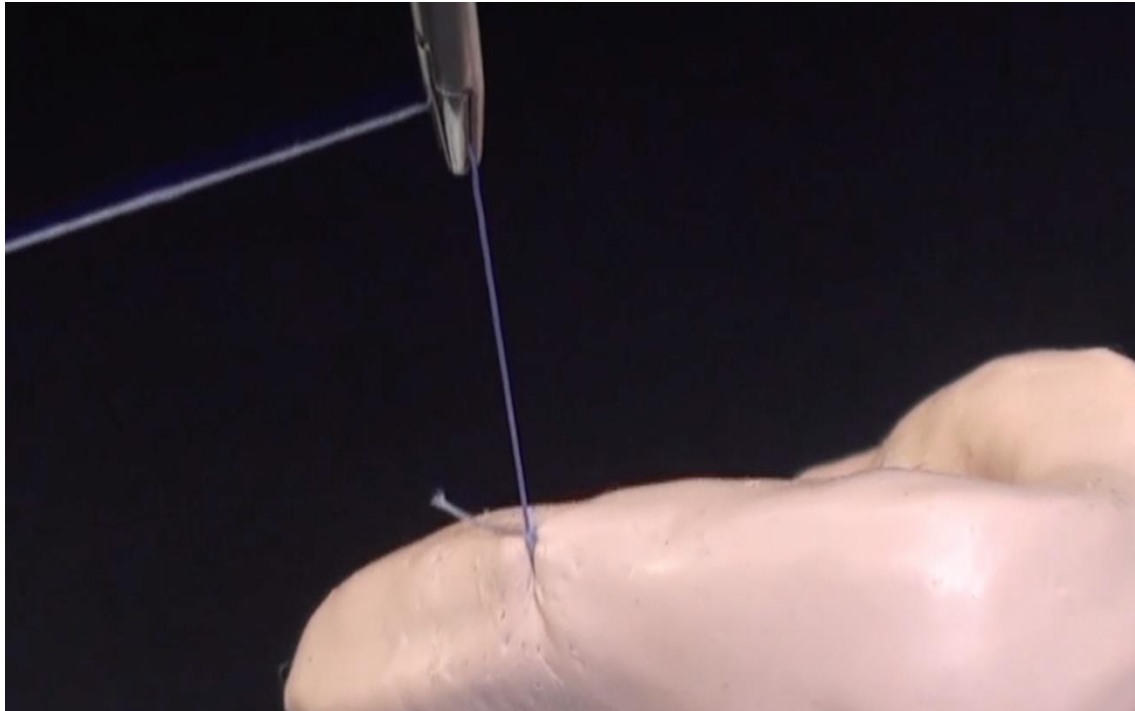


One hand slip knot by a grasper

1 Make a square knot not to be locked the knot.




2 Pull the long tail toward the cannula of a grasper so as to tighten the loop.

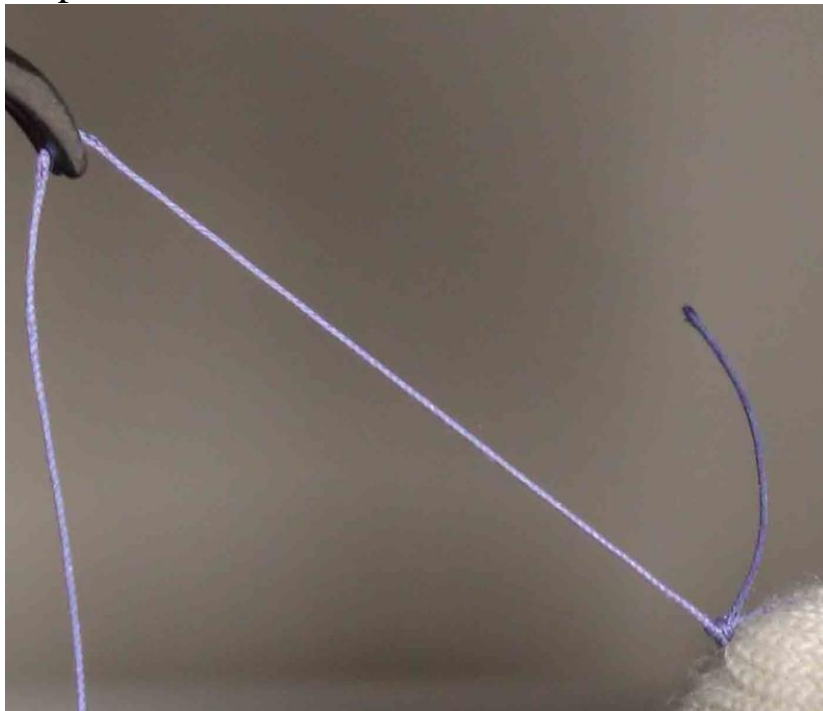


One hand slip knot by a dissector

1 Make a square knot without tightening the knot.



2 Pull the long tail toward the cannula of a dissector so as to tighten the loop.



Training

Intracorporeal suture tying is difficult and requires practice. We recommend that daily practice of 20 minutes morning and evening to develop greater skill and precision. The phrase “Think Globally, Act Locally” is also important during suturing. That means the one should always overlook whole pelvis while working at a specific location.

Training tasks

#1 Reel a suture as quickly as possible

Always work in a specified small area. But, reel the suture with a big stride.

Always watch not a long tail but a short tail of the suture while reeling.

#2 Throw a suture clockwise and counterclockwise alternately.

Do this task so as not to scratch forceps against each other and as quickly as possible at least 20 consecutive times.

#3 Continuous stitching

Make a habit that you stick the needle in a training pad at a one push by a grasper and stick that out by a dissector at a time.

Imaging myomectomy, practice 10 consecutive times smoothly

REFERENCES

Nezhat C, Nezhat F, Nezhat CH. *Nezhat's Video-Assisted and Robotic-Assisted Laparoscopy and Hysteroscopy with DVD*. 4th edition. New York: Cambridge University Press, 2013.

Takayasu K, Yoshida K, Mishima T, Watanabe M, Matsuda T, Kinoshita H. Upper body position analysis of different experience level surgeons during laparoscopic suturing maneuvers using optical motion capture. *Am J Surg*. 2019 Jan;217(1):12-16.

Lim S, Ghosh S, Niklewski P, Roy S. Laparoscopic Suturing as a Barrier to Broader Adoption of Laparoscopic Surgery. *JSLs*. 2017 Jul-Sep;21(3).